Scrotal Kaposi Sarcoma in a HIV-Negative elderly Nigerian. A case report with a review of literature.

Uchendu Jude Obiora*[1], Otene Cletus Ikechukwu.[2]

[1]Department of Morbid Anatomy and Histology, Delta State University, Abraka, Delta State, Nigeria.

[2]Department of Surgery, Delta State University, Abraka, Delta State, Nigeria.

Submitted: 28th Feb., 2023; Accepted: 18th April., 2023; Published: 30th April., 2023
DOI: https://doi.org/10.54117/jcbr.v3i2.2
**Corresponding author:Uchendu Obiora Jude; ojlinksent@gmail.com; 08038732062*

Abstract

Kaposi Sarcoma KS is a rare, borderline vascular tumor that affects the muco-cutanous surfaces, and lymph nodes and visceral organs occasionally. Various forms have been described with a common association with Herpes Simplex virus 8 infection, although immunological, environmental and genetic factors play significant role in its pathogenesis. Urogenital involvement is uncommon and isolated scrotal KS in HIV negative individuals is extremely rare. We therefore report the 5th of such case in English literature, involving a 65 year old Nigerian, with confirmed histological and immunohistochemistry diagnostic features. Patient underwent surgical excision of the lesion and is being considered for chemotherapy.

Keywords: HIV-Negative, Kaposi Sarcoma, Niigerian.

Introduction

Kaposi sarcoma KS is an intermediate-grade angio-proliferative tumor derived from endothelial cells. It is named after Moritz Kaposi, who published three fatal cases of KS as multiple idiopathic pigmented hemangiosarcoma in Vienna in 1872 among elderly males (Kaposi, 1872). It is primarily due to Human Herpes Simplex Virus HHSV-8 infection but in association with certain genetic, environmental and immunological co-factors (Ruocco et al., 2019). Clinically and epidemiologically, four types of Kaposi's sarcoma have been recognized namely the Classic, African endemic, Iatrogenic, and epidemic or Acquired immunodeficiency syndrome AIDS related forms (Ruocco et al., 2019). It manifests most frequently in mucocutaneous sites (skin, oral cavity) although cases in lymph nodes, visceral organs and in unusual sites such as bone have also been described. The clinical course is variable, ranging from indolent, with only skin manifestations to fulminant course with extensive visceral involvement (Kaposi 1872; (Ruocco et al., 2019).

In this paper, we report a rare case of isolated scrotal KS in a 65-year-old retroviral-negative elderly Nigerian male.

Case Report

A 65-year-old Nigerian presented to the surgical out-patient department with slowly growing isolated multiple scrotal nodular rashes which developed over a period of six months. The patient had no history of trauma to the external genitalia, intravenous drug addiction, immunosuppression, homosexual act or blood transfusion. Physical examination

revealed multiple soft pink scrotal pedunculated nodules of 6-10 mm diameter (Figure 1). There is no inguinal lymph node involvement, hepatomegaly or splenomegaly. He is not a known diabetic. Venereal disease research laboratory test (VDRL), retroviral and Mantoux skin test were all negative and wound swab culture and microscopy showed the presence of Staphylococcus epididymis. Histological evaluation of the scrotal nodules showed a neoplastic vascular lesion composed of intersecting fascicles of spindles cells, with intervening blood-filled spaces between the spindle cells. These tumour cells have elongated hyperchromatic nuclei and occasional mitosis (Figure 2A and 2B). Immunohistochemical staining proved positive for HHSV8 antibody (Figure 3). Histological and immunohistochemical features were in keeping with those of KS, classic type.

Discussion

Epidemiologically, the classic KS occur typically among older men of Mediterranean, Central and Eastern European descent. This form may be associated with altered immunity or malignancy but not with HIV infection (Kaposi, 1872; Ruocco et al., 2019). It usually follows an indolent course and manifests as multiple red-purple skin nodules, mainly in the lower limb (85-95% of cases) and trunk (9-15% of cases) (Mitre et al., 2017). Though a good number of cases have been encountered in the penile shaft, scrotal KS is extremely rare (Kim et al., 2010). The first case of isolated scrotal KS was reported by Vyas et al in 1976 (Vyas et al., 1976). A case was also reported in a 48-year Nigeria, in 2014, but with retroviral positive status (Tela et al., 2014). Isolated scrotal KS is very rare among retroviral negative individuals and only 4 cases have been reported in medical literature (Yenis et al., 2018). Our report is probably the 5th of such cases. The etiology of Kaposi sarcoma is still not been fully elucidated. Epidemiological studies have confirmed that Human Herpes Simplex 8 (Kaposi sarcoma virus) infection is seen in all forms KS, but an insufficient condition for the development of the disease. HHV-8 contains homologues of cellular genes that stimulate cell proliferation, inflammation and angiogenesis, while suppressing apoptosis. Complex interaction including gene polymorphism, exposure to chemicals, drugs, viral infections, systemic and local immunodeficiency are important co-factors for the development of KS among patients infected with KSHV 8 (Ruocco et al., 2019). Diagnosis of KS is based on clinical assessment which is further confirmed by using light microscopic evaluation of Hematoxylin and eosin-stained tissue sections. Atypical cases can be further confirmed using HHV8 antibodies and endothelial markers such as factor VIII–related antigen, CD31 (PECAM-1), and CD34 to demonstrate that they are of vascular origin. The index case was strongly positive for HHV8 and CD34 antibodies. Molecular diagnosis can also be made using PCR to identify Kaposi sarcoma viral DNA. This is positive in over 95% of epidemiological forms of KS (Cesarman, 2019).

The management of KS depends on the patient's symptoms, extent, and the rate of tumor growth, immune status and concurrent HIV-related complications in case of HIV-positive cases, but is generally aimed at relieving symptoms, reducing the size and number of lesions, and slowing down the disease progression. Treatment options include tumor excision, chemotherapy, laser ablation, cryotherapy, electrocautery, radiotherapy, intra-lesion or systemic injection of cytotoxic agents, adjuvant therapy with alpha and beta interferon, and photodynamic therapy using nitrogen mustard or imiquimod (Ruocco et al., 2019; Soufiane et al., 2010).

The index case had surgical excision of the nodules and is been planned for chemotherapy. In conclusion, localized scrotal KS is a very rare vascular neoplasm, and even less common among the HIV-sero-negative individuals. The gold standard of diagnosis is histology with or without immunohistochemistry confirmation using HHV8 and endothelial antibody markers. There are different available treatment modalities that are tailored to the need of the patient (Soufiane et al., 2010).

Reference

Cesarman E, Damania B, Krown SE, Martin J, Bower M, Whitby D (2019): Kaposi sarcoma. Nat Rev Dis Primers. 5, 9.

Kaposi M (1872): Idiopathisches multiples Pigment sarkom der Haut. Arch Dermatol Syph. 4, 265-273.

Kim KH, Choi JI, Ryu KH, Kang IH, Leng YH, Lee JW, et al (2010): Primary classic Kaposi's sarcoma of the penis in an HIV-negative patient. Korean J Urol. 51, 803–806.

Mitre V, Applebaum D, Potenziani S, Hsu S (2017): Classic Kaposi sarcoma in an HIV-negative Han Chinese man: a case report. DOJ. 23, 11.

Ruocco E, Vincenzo Ruocco, Tornesello ML, Gambardella A, Ronni Wolf R, Buonaguro FM (2019): Kaposi's sarcoma: Etiology and pathogenesis, inducing factors, causal associations, and treatments: Facts and controversies. Clinics in Dermatology 31, 413–422.

Soufiane M, Fadl TM, Nawfel M, Ouafae M, Kawtar Z, Afaf L, et al (2010): Kaposi's sarcoma: HIV negative man with isolated penile localization. Indian J Pathol Microbiol. 53, 535–536.

Tela UM, Ibrahim AG, Abubakar AS, WaruGoni B, Musa AB, Waziri A (2014): Localized Primary Kaposi's sarcoma of the Scrotum: A rare presentation. IOSR-JDMS.13 (3), 83-85.

Vyas S, Manabe T, Herman JR, Newman HR (1976): Kaposi's sarcoma of scrotum. Urology. 8, 82–85.

Yenice MG, Varnali E, Seker KG, Kavak A, Tugcu V (2018): Scrotal Kaposi's Sarcoma in HIV negative patient: A case report and review of the literature. Turk J Urol. 44(2), 182–184.



Figure 1: Scrotum of Patient with Kaposi sarcoma

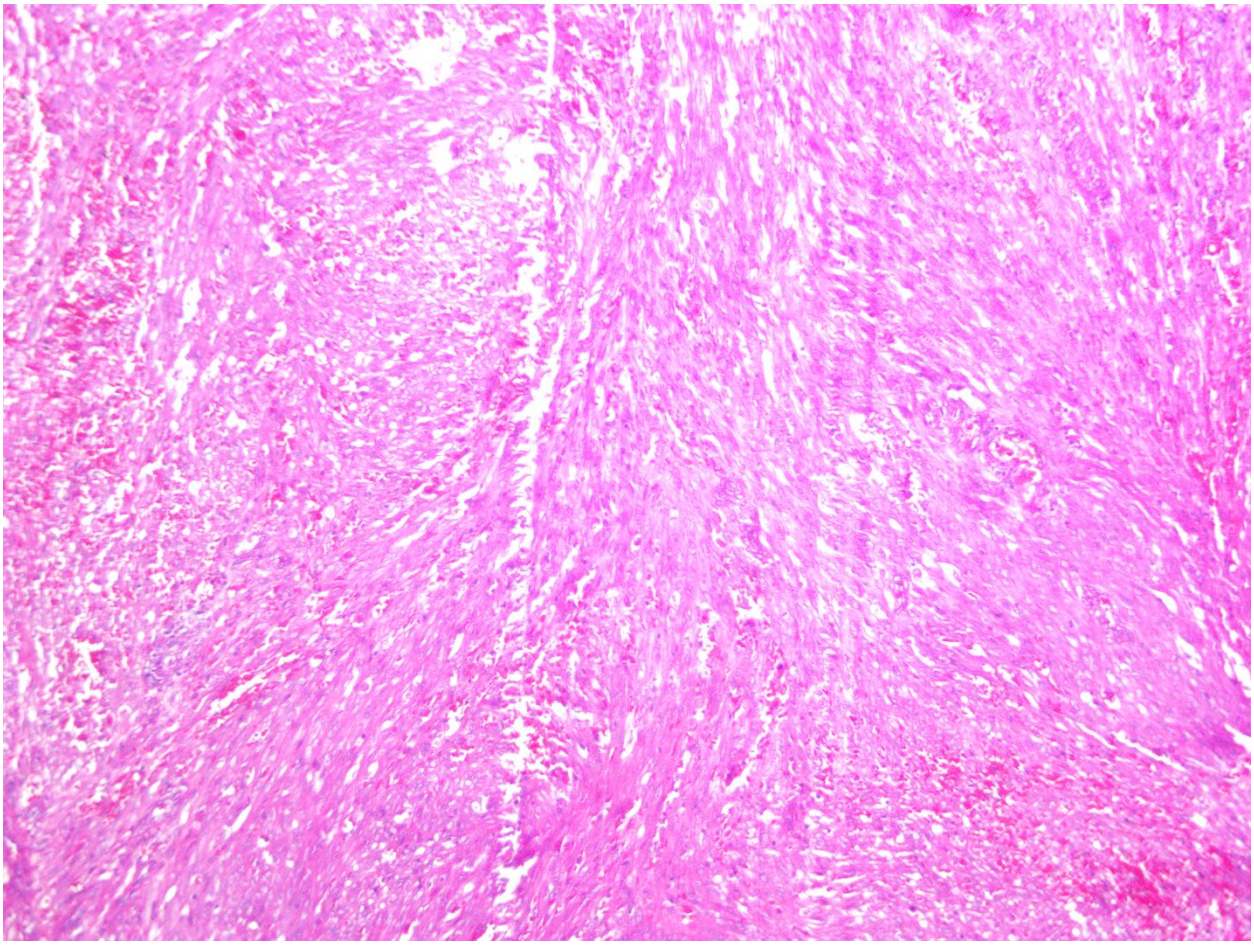

Figure 2A: Histological section of Skin lesion showing features of Kaposi Sarcoma (X10 magnification)

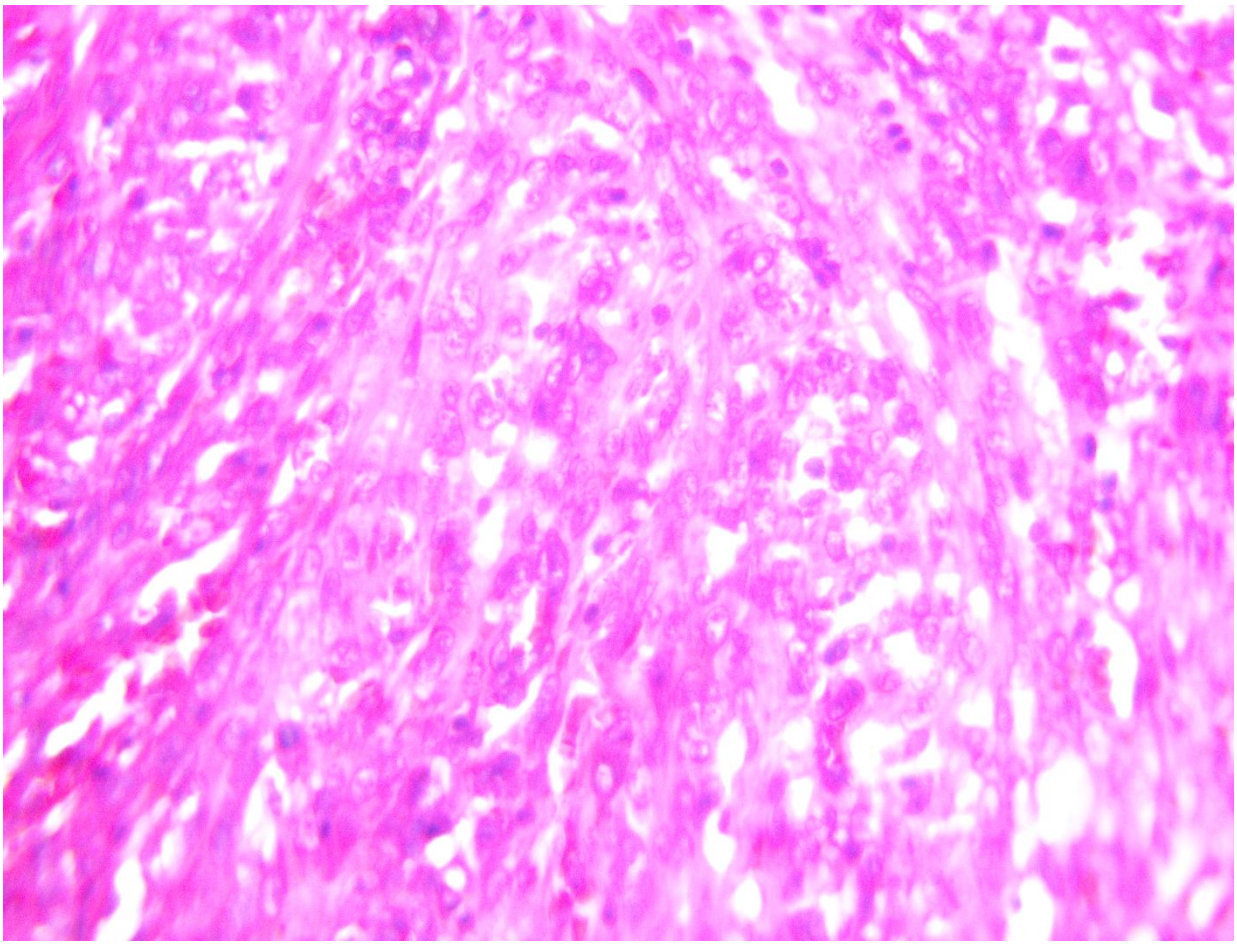

Figure 2A: Histological section of Skin lesion showing features of Kaposi Sarcoma (X40 magnification)

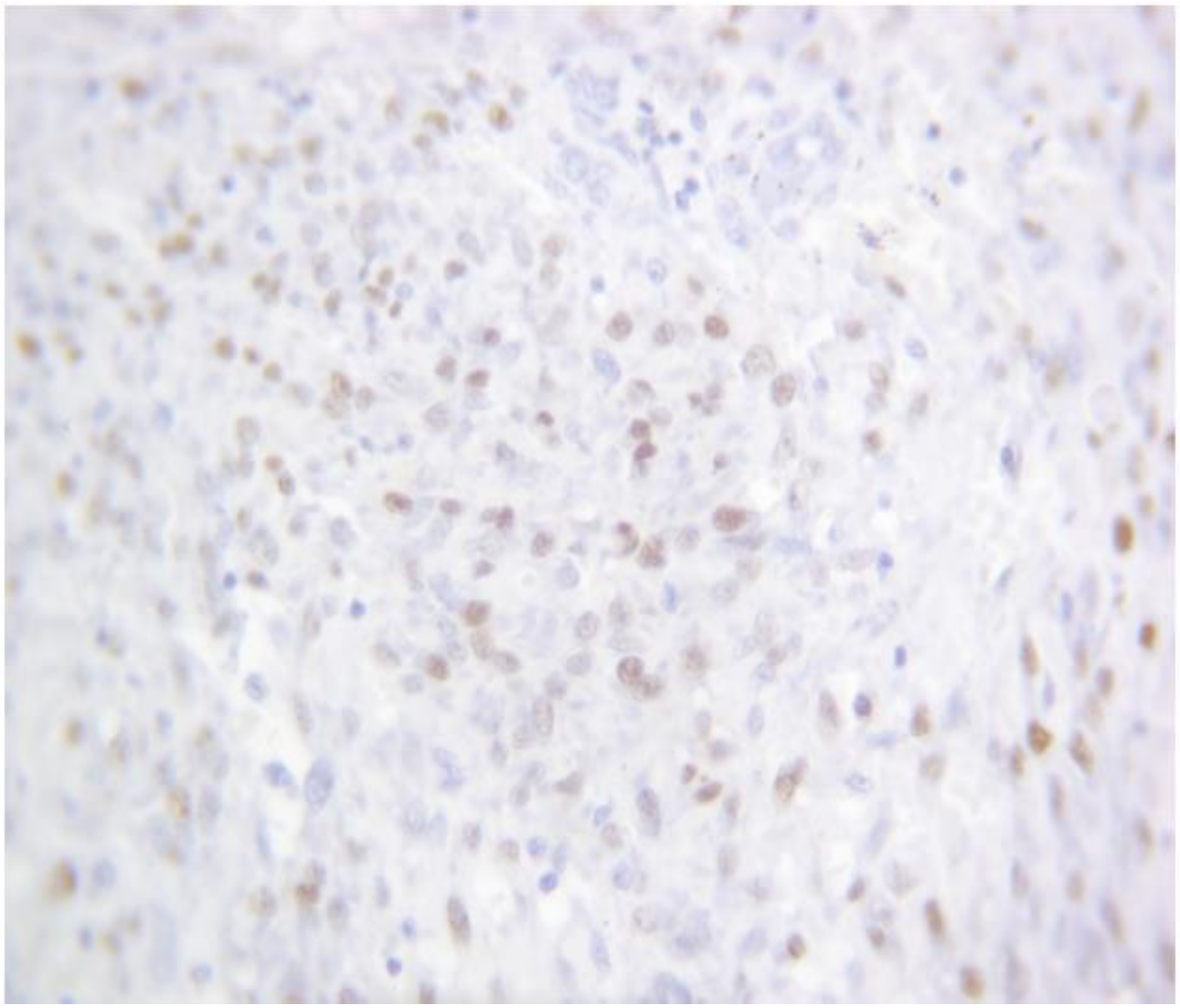

Figure 3: Immunohistochemical stain, positive for Human Herpes Simplex 8 antibody (X40 magnification)