Safety of combined hydro-ethanolic *Moringa oleifera* (Moringaceae) seed extract and metformin therapy in Wistar rats: a 91-day sub-chronic toxicity study

Bashir A.I.J.*[1], Tanimu Y.D.[1], Sulaiman T.[1], Mallam D.[1], Abubakar A.[2]

[1]Department of Pharmacology and Toxicology, Faculty of Pharmaceutical Sciences, Kaduna State University, Kaduna-Nigeria
[2]Department of Pharmacology and Therapeutics, Ahmadu Bello University, Zaria, Nigeria

Submitted: 8th August, 2026; Accepted: 27th August, 2026; Published online: 31st August, 2026
DOI: https://doi.org/10.54117/jcbr.v6i4.3
*Corresponding Author: Bashir A.I.J; asmau1981.bashir@gmail.com; +2348100348071

Abstract

Moringa oleifera (MO) is a common medicinal plant used due to its numerous medicinal properties. Metformin has been found to have better antihyperglycemic effects when used in combination with MO than metformin alone. However, there is little information about its toxicity profile when used in combination with metformin. This study evaluated the toxicological effects of repeated oral administration of *Moringa oleifera* (MO) seed extract in combination with Metformin (MET) in Wistar rats. A total of six groups of male and female rats were administered distilled water (1 mL/kg), MET (125 mg/kg), MO extract (1000 mg/kg), and combinations of MO (250, 500, and 1000 mg/kg) with MET (125 mg/kg) respectively over a 91-day period. Mortality was observed across five groups. Results showed a progressive increase in feed intake across all groups, with no statistically significant difference ($p>0.05$) compared to the control. Similarly, water intake remained relatively stable throughout the study duration. Relative organ weights showed no significant differences ($p>0.05$), suggesting the absence of treatment-related atrophy. Only white blood cells (WBC) showed a significant ($p<0.05$) increase compared to the control. Urea levels ranged from 10.1±0.4 to 12.8±3.5 mmol/L in females and 6.5±0.35 to 8.6±1.00 mmol/L in males. Creatinine levels showed a significant increase ($p < 0.05$) in females treated with MO500+MET125 and in males treated with MET125 alone, compared to control values of 40.0±0.10 µmol/L (female) and 39.0±12.0 µmol/L (male). Electrolyte levels remained unchanged across all groups. Alanine aminotransferase (ALT) levels showed significant reduction in both male and female groups, while aspartate aminotransferase (AST) was significantly reduced only in females treated with MET (125 mg) and MO (250 mg). Alkaline phosphatase (ALP), total protein (TP), and albumin (ALB) showed no significant differences compared to the control. Histological examination of kidney tissues revealed normal glomerular and tubular structures in all groups, indicating preserved renal architecture. However, mild hepatocyte degeneration was observed in the MO1000+MET125 group, suggesting a possible dose-related hepatic effect at the highest combination dose. Thus, combination may warrant caution because of the mortality, mild hepatocellular degeneration, and selected biochemical alterations observed.

Keywords: Combination therapy, *Moringa oleifera*, Metformin, Sub-chronic toxicity studies

Introduction

In the field of integrative pharmacology, combination therapy has increasingly incorporated phytochemicals and herbal extracts as adjuvants or synergizers in drug regimens (Chaachouay, 2025). These natural product-based agents may enhance drug absorption, modulate metabolic pathways, inhibit efflux mechanisms, or provide additive effects on oxidative stress, inflammation, or cell signalling (Zhou *et al*., 2023). It is currently acknowledged that a large population of people depend on medicinal plants to treat diseases, which is mainly due to ancestral knowledge and reduced cost (Izah *e*t *al*., 2024). This leads to the use of herbal and orthodox medicine simultaneously. It is thus important for plants to be evaluated for their toxicity when used in combination with orthodox drugs (Ebadi, 2025).

Toxicological assessment is an important component of drug discovery and development, particularly for herbal medicines that are often presumed safe due to their natural origin. The objective of such studies is to establish the safety profile of bioactive extracts and compounds through acute, sub-chronic, and chronic toxicity assessments using both *in vitro* and *in vivo* models.

Moringa oleifera (MO) is a common medicinal plant used due to its numerous medicinal properties (Pareek *et al*., 2023) and has been found to have better antihyperglycemic effects when used in combination with metformin than metformin alone. However, there is little information about its toxicity profile when used in combination with metformin (Bashir *et al*., 2025a). This study evaluated the toxicity effects of MO seed extract and metformin combination over a period of 91 days in Wistar rats, which is significantly longer than the 28-day toxicity studies previously carried out by Bashir *et al*. (2025b).

Materials and methods

Experimental animals

Male and female Wistar rats weighing 125-175 g was obtained from the Animal House of the Department of Pharmacology and Toxicology, Kaduna State University, Nigeria. The rats were kept in properly ventilated plastic cages in a conducive laboratory environment and provided standard laboratory animal feed (Ultima finisher feed) and water *ad libitum*. They were treated in accordance with the National Institute of Health (NIH) Guide for the care and use of Laboratory Animals (Production No. 85-23, revised, 1996) and approved Institutional Research and Ethical Committee (Protocol Number; DPTAC/IVT-IVV/01500021). All experimental procedures were reviewed and approved by the University Animal Ethics Committee, Faculty of Pharmaceutical Sciences, Kaduna State University, Nigeria.

Collection of plant material

Moringa oleifera seeds were collected from Zaria, Kaduna State in the month of October, 2025. The seed was identified and authenticated in the Herbarium of Biological Sciences Department of Kaduna State University, by a taxonomist, Mallam US Gallah and was given a voucher number KASU/BSH/878 by comparing with a voucher specimen previously deposited in the herbarium as a reference.

Preparation of seed extract

The seeds of *Moringa oleifera* were cleaned and shade-dried for four weeks. The seeds were crushed using a mortar and pestle and sieved into a fine powder. The powdered seeds (800 g) was macerated in 4.0 litres of 70% v/v ethanol in a closed container, at room temperature for 14 days, with periodic shaking. It was filtered using a filter paper and the filtrate was transferred into an evaporating dish and oven-dried at 50 ℃. The extract was weighed to be 57 g and the percentage yield calculated as 7.13%. The extract was then labelled as *Moringa*

oleifera (MO) extract and stored in an airtight container, at 4℃, protected from light and moisture until required for the main experiment.

Sub-acute toxicity studies

The study was performed in compliance with Organization for Economic Cooperation and Development's (OECD) guidelines for repeated dose 91-day oral toxicity studies in rodents (OECD 408, 1998). The rats (120) were allocated into six groups of twenty rats with ten males and ten females in each group. Group 1 was the control and was given distilled water (1 mL/kg). Group 2 was given Metformin (125 mg/kg) only. Group 3 was given MO (1000 mg/kg) alone. Group 4 was given ethanol extract of MO seeds (250 mg/kg) and metformin (125 mg/kg). Group 5 was given ethanol extract of MO seeds (500 mg/kg) and metformin (125 mg/kg) and Group 6 was given ethanol extract of MO seeds (1000 mg/kg) and metformin (125 mg/kg). The administration carried out orally and daily for 91 days. The body weight of each rat was observed on the 0-day as baseline, 7th day, 14th day, 21st day and 28th day, 35th day, 42nd day, 49th day, 56th day, 63rd day, 70th day, 77th day, 84th and 91st day after which they were anaesthetized with ketamine (90 mg/kg) Kumar and Clover (2015). Animals were then sacrificed. Their organs were harvested and blood sample was collected for further investigations.

Determination of relative organ weight

The kidneys, liver, brain, ovaries, testes and heart were isolated and weighed. The relative organ weight was determined using the formula below;

$$\text{Relative organ weight (\%)} = \frac{\text{Weight of organ (g)}}{\text{Final weight of rat (g)}} \times 100$$

Evaluation of haematological parameters

Portion of the blood samples were collected into EDTA bottles to prevent coagulation. These samples were then subjected to haematological analysis for levels of white blood cells (WBC), red blood cells (RBC), hemoglobin (HGB) and hematocrit/packed cell volume PCV (HCT) using an auto-hematology analyzer (Sysmex USA) (Abubakar *et al*., 2023).

Evaluation of electrolytes and renal biochemical parameters

Blood samples were collected and centrifuged at 1000 rpm for 10 minutes and separated serum was analyzed for electrolytes and biochemical parameters related to the kidneys such as Creatinine (Bartels *et al*., 1972), Urea (Weatherburn 1976). The levels of Sodium, Potassium, Chlorine and Bicarbonate were also determined with the aid of a Hitachi 902 analyzer (Roche, Germany) as reported by Abdulhakim *et al*. (2025).

Evaluation of hepatic biochemical parameters

Blood samples for liver-function tests was collected in plain sample bottles and centrifuged for 10 minutes at 3500 rpm to obtain the serum. The serum was analysed for liver function parameters including Alanine amino Transferase (ALT) and Aspartate amino transferase (AST) (Reitman and Frankel 1957), alkaline phosphatase (ALP) (Belfield and Goldberg 1971), Albumin (ALB) and Total protein (TP) (Doumas *et al*. 1971) and Total bilirubin (TB) (Walters and Gerarde, 1970).

Histopathology

The livers and kidneys were fixed for 10 days in 10% formaldehyde. They were then dehydrated, cleared and infiltrated with paraffin wax. Then, the organs were embedded and sectioned. Five micrometer sections of the organs were made with the aid of microtome, kept on the slide and was stained with hematoxylin and eosin. The sections were then viewed under a microscope for histomorphological lesions (Arthur and John, 1978).

Statistical analysis

Data evaluation was carried out with the aid of SPSS software (Version 20) and was

presented as mean ± standard error of the mean (S.E.M). Variations between means were examined by one way ANOVA and repeated measure ANOVA, followed by an appropriate post-hoc test. Values of $p \leq 0.05$ were considered statistically significant. The results were presented in charts and tables where applicable

Results

Effect of 91-day daily administration of MO seed extract in combination with MET on general behaviour and mortality

No consistent or obvious clinical signs of toxicity such as changes in movement, feeding behaviour, aggression, or nervous system problems across the groups throughout the study period. The animals appeared to maintain normal body function. However, mortality was recorded in some groups; One male in the group of rats administered distilled water, three females in the group administered MO extract alone, one male each in groups administered 250 mg MO extract in combination with metformin and 500 mg MO extract in combination with metformin alongside two females in the group that was administered 1000 mg of MO extract in combination with metformin.

Effect of 91-day daily administration of MO seed extract in combination with MET on feed and water intake in Wistar rats

The intake of MO extract combination with metformin did not produce any significant effect on feed and water intake in both female and male rats when compared with the control throughout the study period as presented in (Tables 1 and 2).

Table 1: Effect of 91-day daily administration of *Moringa oleifera* seed extract in combination with metformin on feed intake in Wistar rats

	FEED INTAKE (g)												
DURATION OF TREATMENT (DAY)	**7**	**14**	**21**	**28**	**35**	**42**	**49**	**56**	**63**	**70**	**77**	**84**	**91**
Female													
D/W 1mL/kg	182±0.52	184±0.23	170±0.34	160±0.51	150±0.13	190±0.13	200±0.24	190±0.28	170±0.17	190±0.48	170±0.32	175±0.20	190±0.33
MET125	180±0.43	182±0.32	176±0.42	165±0.21	157±0.12	198±0.32	208±0.38	197±0.19	174±0.21	186±0.30	167±0.32	178±0.15	197±0.37
MO1000	200±0.32	145±0.31	180±0.32	175±0.32	183±0.22	174±0.43	200±0.52	190±0.11	185±0.15	170±0.25	200±0.32	190±0.33	200±0.21
MO250+MET125	203±0.32	136±0.42	178±0.16	178±0.34	181±0.12	179±0.33	202±0.21	196±0.42	187±0.31	168±0.22	203±0.23	197±0.54	205±0.23
MO500+MET125	120±0.10	140±0.24	180±0.32	200±0.21	190±0.11	160±0.12	185±0.28	175±0.39	200±0.47	195±0.23	180±0.30	200±0.22	180±0.21
MO1000+MET125	122±0.33	146±0.31	176±0.32	189±0.28	185±0.19	167±0.20	188±0.32	174±0.34	207±0.14	193±0.45	189±0.26	208±0.11	177±0.28
Male													
D/W 1mL/kg	129±0.43	131±0.25	120±0.62	132±0.53	182±0.32	188±0.24	196±0.52	197±0.13	189±0.21	179±0.23	185±0.22	197±0.36	198±0.41
MET125	134±0.23	136±0.21	127±0.34	137±0.52	184±0.32	193±0.53	201±0.32	195±0.12	182±0.21	183±0.33	179±0.31	186±0.21	181±0.32
MO1000	234±0.47	160±0.32	152±0.33	157±0.21	189±0.16	165±1.79	175±0.22	195±0.41	200±0.51	140±0.53	187±0.63	196±0.34	185±0.41
MO250+MET125	197±0.65	180±0.23	161±0.32	145±0.23	170±0.32	177±0.22	170±0.12	185±0.32	220±0.22	146±0.36	172±0.52	190±0.26	186±0.32
MO500+MET125	152±0.32	140±0.21	156±0.31	146±0.24	181±0.43	160±0.12	170±0.32	177±0.23	185±0.51	184±0.12	190±0.35	205±0.41	192±0.46
MO1000+MET125	148±0.42	143±0.11	145±0.15	137±0.16	172±0.31	166±0.36	180±0.31	175±0.32	190±0.24	180±0.53	198±0.35	200±0.13	195±0.32

Values are mean ±SEM; no significant changes compared with D/W group using one-way ANOVA. D/W=distilled water, MET125=metformin (125 mg/kg) alone, MO1000= *Moringa oleifera* seed extract (1000 mg/kg) alone, MO250+MET125=*Moringa oleifera* seed extract (250 mg/kg) and metformin (125 mg/kg), MO500+MET125=*Moringa oleifera* seed extract (500 mg/kg) and metformin (125 mg/kg), MO1000+MET125= *Moringa oleifera* seed extract (1000 mg/kg) and metformin (125 mg/kg).

Table 2: Effect of 91-day daily administration of *Moringa oleifera* seed extract in combination with metformin on water intake in Wistar rats

	WATER INTAKE (mL)												
DURATION OF TREATMENT (DAY)	**7**	**14**	**21**	**28**	**35**	**42**	**49**	**56**	**63**	**70**	**77**	**84**	**91**
Female													
D/W 1mL/kg	510±0.13	400±0.13	370±0.14	490±0.12	475±0.20	380±0.21	400±0.13	445±0.19	510±0.00	480±0.12	440±0.22	500±0.41	465±0.13
MET125	500±0.23	405±0.34	350±0.23	480±0.14	480±0.44	385±0.23	420±0.49	450±0.61	500±0.50	495±0.21	460±0.11	510±0.12	470±0.19
MO1000	505±0.23	500±0.42	525±0.18	450±0.11	505±0.10	500±0.23	470±0.26	500±0.34	500±0.32	505±0.23	450±0.20	272±0.21	550±0.30
MO250+MET125	500±0.31	520±0.22	500±0.12	460±0.26	500±0.45	510±0.20	490±0.27	530±0.51	510±0.12	500±0.26	450±0.12	275±0.46	500±0.21
MO500+MET125	370±0.30	500±0.21	400±0.23	500±0.32	510±0.24	480±0.32	455±0.31	500±0.46	490±0.31	500±0.10	460±0.20	450±0.23	575±0.34
MO1000+MET125	450±0.23	510±0.32	420±0.11	505±0.18	500±0.42	470±0.31	450±0.40	510±0.38	480±0.42	535±0.33	470±0.41	460±0.22	500±0.23
Male													
D/W 1mL/kg	530±0.00	455±0.12	355±0.16	270±0.13	310±0.21	550±0.14	480±0.14	540±0.20	480±0.17	450±0.11	525±0.19	410±0.21	510±0.22
MET125	525±0.43	440±0.24	350±0.21	290±0.22	305±0.22	520±0.29	490±0.31	510±0.17	470±0.21	455±0.32	510±0.30	402±0.34	505±0.52
MO1000	370±0.11	400±0.21	525±0.23	250±0.22	365±0.25	230±0.12	420±0.21	350±0.18	510±0.12	470±0.17	505±0.16	420±0.34	520±0.43
MO250+MET125	380±0.61	410±0.22	500±0.32	258±0.23	370±0.22	240±0.13	400±0.34	340±0.21	500±0.22	490±0.42	500±0.40	430±0.23	500±0.44
MO500+MET125	340±0.34	500±0.15	410±0.22	480±0.41	360±0.26	200±0.32	340±0.31	500±0.42	480±0.21	480±0.30	325±0.13	460±0.12	320±0.56
MO1000+MET125	350±0.22	520±0.21	400±0.14	470±0.17	350±0.30	210±0.32	350±0.38	510±0.25	470±.27	485±0.35	350±0.12	430±0.24	350±0.75

Values are mean ±SEM; no significant changes compared with D/W group using one-way ANOVA. D/W=distilled water, MET125=metformin (125 mg/kg) alone, MO1000= *Moringa oleifera* seed extract (1000 mg/kg) alone, MO250+MET125=*Moringa oleifera* seed extract (250 mg/kg) and metformin (125 mg/kg), MO500+MET125=*Moringa oleifera* seed extract (500 mg/kg) and metformin (125 mg/kg), MO1000+MET125= *Moringa oleifera* seed extract (1000 mg/kg) and metformin (125 mg/kg).

Effect of 91-day daily administration of MO seed extract in combination with MET on body weights

The intake of MO extract combination with metformin did not produce any significant effect on the body weights compared to the control, metformin alone and MO extract alone in both female and male rats (Figure 1).

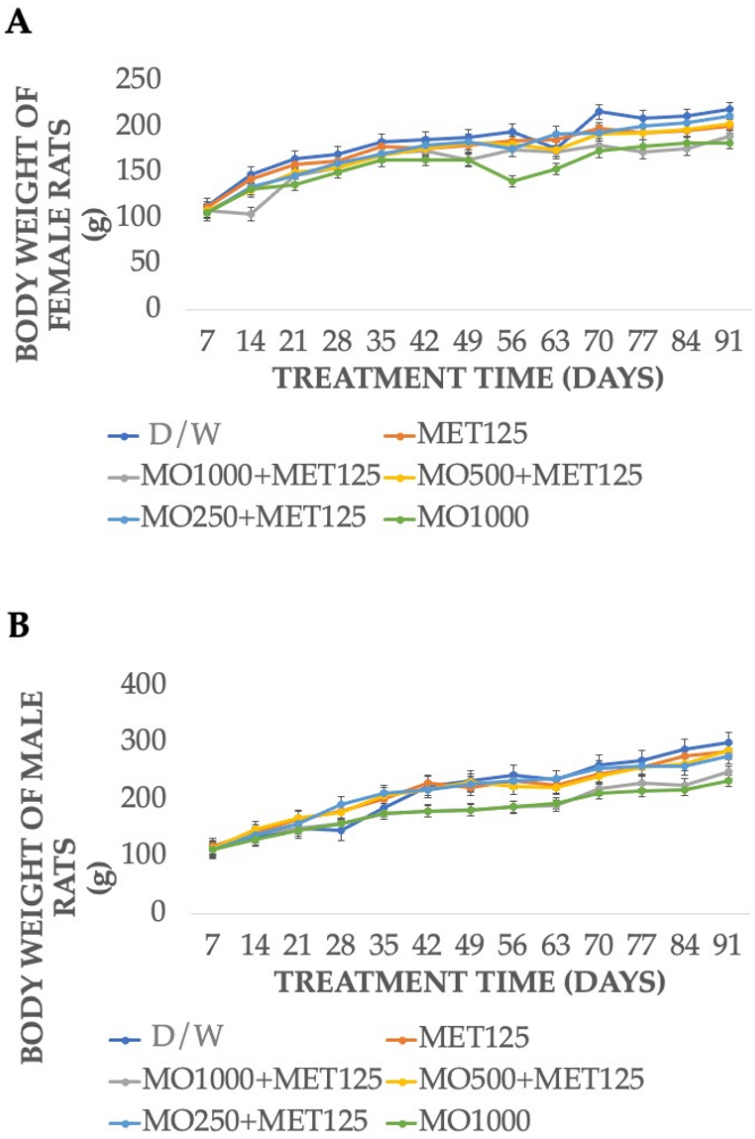

Figure 1. Effect of 91-day daily administration of *Moringa oleifera* seed extract in combination with Metformin on body weight of Wistar Rats: A (Female) and B (Male) Values are mean±SEM. D/W= Distilled water, MET 125= Metformin (125 mg/kg) alone, MO1000+MET125= *Moringa oleifera* seed extract (1000 mg/kg) and Metformin (125 mg/kg), MO500+MET125= *Moringa oleifera* seed extract (500 mg/kg) and Metformin (125 mg/kg), MO250+MET125= *Moringa oleifera* seed extract (250 mg/kg) and Metformin (125 mg/kg), MO1000= *Moringa oleifera* seed extract (1000 mg/kg) alone.

Effect of 91-day daily administration of MO seed extract in combination with MET on relative organ weight

The effect of MO seed extract and metformin on relative organ weights is presented in Table 3. No significant changes were observed in any of the test groups.

Table 3: Effect of 91-day daily administration of *Moringa oleifera* seed extract in combination with Metformin on relative organ weight of Wistar Rats

	Treatment (mg/kg)					
Parameters (%)	D/W 1 mL/kg	MET125	MO1000	MO250+MET125	MO500+MET125	MO1000+MET125
Female						
Kidney	1.30±0.13	1.26±0.21	1.10±0.81	1.22±0.16	1.20±0.21	1.24±0.15
Liver	5.30±0.87	4.88±0.30	4.47±0.68	4.36±0.65	4.18±2.07	5.46±1.07
Ovaries	0.42±0.4	0.46±0.10	0.30±0.08	0.30±0.09	0.40±0.60	0.35±0.26
Brain	1.26±0.22	1.16±0.27	1.20±0.81	1.14±0.10	1.10±0.17	1.35±0.27
Heart	0.90±0.21	0.82±0.19	0.83±0.12	0.82±0.12	0.86±0.24	0.80±0.19
Male						
Kidney	1.98±0.40	1.82±0.37	1.60±0.21	1.83±0.33	1.87±0.21	1.50±0.30
Liver	9.33±2.07	8.84±1.70	7.43±0.78	8.55±1.50	9.07±1.39	7.95±2.05
Testes	3.83±0.04	3.72±0.77	2.93±0.33	3.06±0.45	3.17±0.12	2.85±0.25
Brain	1.4±0.19	1.26±0.14	1.18±0.25	1.08±0.33	1.23±0.48	1.05±0.15
Heart	1.0±0.20	1.04±0.19	0.90±0.27	1.10±0.23	1.03±0.12	0.97±0.04

Values are mean±SEM; no significant changes compared with D/W group using one-way ANOVA. D/W=distilled water, MET125=metformin (125 mg/kg) alone, MO1000= *Moringa oleifera* seed extract (1000 mg/kg) alone, MO250+MET125=*Moringa oleifera* seed extract (250 mg/kg) and metformin (125 mg/kg), MO500+MET125=*Moringa oleifera* seed extract (500 mg/kg) and metformin (125 mg/kg), MO1000+MET125= *Moringa oleifera* seed extract (1000 mg/kg) and metformin (125 mg/kg).

Effect of 91-day daily administration of MO seed extract in combination with MET on haematological indices

The administration of MO extract with metformin combination produced an elevation of WBC count in the female group of rats administered MO extract alone and a decrease in WBC count in the male group of rats also administered MO extract alone.

Table 4: Effect of 91-day daily administration of *Moringa oleifera* seed extract in combination with metformin on haematological indices of Wistar Rats

		Treatment (mg/kg)					
Parameters	Units	D/W 1 mL/kg	MET125	MO1000	MO250+MET125	MO500+MET125	MO1000+MET125
Female							
WBC	($\times 10^3$ /µL)	3.2±0.81	5.7±0.96	5.8±1.07*	4.0±2.22	5.1±0.78	5.4±1.66
RBC	($\times 10^6$ /µL)	6.7±0.27	7.4±0.41	6.6±0.38	7.6±0.62	7.9±0.86	6.6±0.38
HGB	(g/dL)	12.6±0.49	13.6±0.80	13.3±0.47	13.8±0.75	14.2±0.98	12.5±0.50
HCT	(%)	38.2±1.17	40.6±2.87	41.0±2.16	42.2±1.74	42.4±2.94	38.3±1.30
Male							
WBC	($\times 10^3$ /µL)	8.1±1.93	6.1±1.01	3.7±1.33*	8.9±1.54	6.1±0.83	1.3±0.36
RBC	($\times 10^6$ /µL)	8.8±1.01	8.2±2.33	9.9±0.92	6.6±1.51	6.8±2.87	11.2±1.63
HGB	(g/dL)	17.8±0.83	17.0±0.89	15.3±0.63	15.3±1.09	15.0±0.82	15.0±1.00
HCT	(%)	53.8±1.92	51.8±2.14	46.3±1.48	46.3±2.49	45.3±2.05	45.0±3.00

Values are mean±SEM; significant changes compared with D/W group using one-way ANOVA followed by Tukey's post hoc test *($p<0.05$). WBC=white blood cell count, RBC=red blood cell count, HGB=hemoglobin, HCT=hematocrit, D/W=distilled water, MET125=metformin (125 mg/kg) alone, MO1000= *Moringa oleifera* seed extract (1000 mg/kg) alone, MO250+MET125=*Moringa oleifera* seed extract (250 mg/kg) and metformin (125 mg/kg), MO500+MET125=*Moringa oleifera* seed extract (500 mg/kg) and metformin (125 mg/kg), MO1000+MET125= *Moringa oleifera* seed extract (1000 mg/kg) and metformin (125 mg/kg).

Effect of 91-day daily administration of MO seed extract in combination with MET on electrolytes and renal indices

The effect of MO seed extract and metformin on renal indices is presented in Table 5. Creatinine levels were significantly elevated in the female group that received 500 mg/kg MO seed extract in combination with 125 mg/kg of metformin. Creatinine levels were also elevated in male group that received 125 mg/kg of metformin alone.

Table 5: Effect of 91-day daily administration of *Moringa oleifera* seed extract in combination with metformin on renal indices and electrolytes of Wistar Rats

Treatment (mg/kg)	Urea (mmol/L)	Creatinine (µmol/L)	Sodium (mmol/L)	Chloride (mmol/L)	Potassium (mmol/L)	Bicarbonate (mmol/L)
Female						
D/W 1mL/kg	10.3±0.6	40.0±0.10	141.8±5.46	99.8±2.80	4.0±1.36	27.0±3.72
MET125	10.1±0.4	47.8±0.80	143.4±4.78	80.8±2.60	4.0±1.11	28.0±2.23
MO1000	10.2±0.5	39.6±0.34	142.6±5.69	99.6±2.21	4.1±1.52	28.0±2.20
MO250+MET 125	10.9±0.7	58.8±0.07	142.4±6.40	100.8±6.66	4.3±1.37	27.8±7.60
MO500+MET 125	12.8±3.5	71.5±0.07*	142.2±8.23	99.0±7.45	4.1±0.72	29.2±9.48
MO1000+MET 125	11.9±0.5	32.0±0.09	142.8±6.10	39.6±2.22	4.0±0.33	27.8±2.92
Male						
D/W 1mL/kg	8.6±1.00	39.0±12.0	142.0±5.83	99.8±2.77	4.1±0.79	27.3±9.49
MET125	8.5±1.40	69.4±9.00*	143.4±4.98	101.4±3.86	4.0±0.54	28.0±5.61
MO1000	7.5±0.30	37.8±3.50	142.0±4.62	101.0±3.88	4.4±1.87	27.3±6.13
MO250+MET 125	6.5±0.35	27.5±4.00	141.3±7.08	99.0±5.40	4.0±6.97	27.8±7.68
MO500+MET 125	7.6±0.32	26.6±3.20	145.6±4.00	102.3±5.35	3.8±2.22	29.6±3.95
MO1000+MET 125	8.2±0.65	36.5±10.30	138.5±9.37	98.0±10.66	4.4±1.00	26.5±9.87

Values are mean ±SEM; significant changes compared with D/W group using one-way ANOVA followed by Tukey's post hoc test *($p<0.05$). D/W=distilled water, MET125=metformin (125 mg/kg) alone, MO1000=*Moringa oleifera* seed extract (1000 mg/kg) alone, MO250+MET125=*Moringa oleifera* seed extract (250 mg/kg) and metformin (125 mg/kg), MO500+MET125=*Moringa oleifera* seed extract (500 mg/kg) and metformin (125 mg/kg), MO1000+MET125= *Moringa oleifera* seed extract (1000 mg/kg) and metformin (125 mg/kg).

Effect of 91-day daily administration of MO seed extract in combination with MET on hepatic indices

The effect of MO seed extract and metformin on liver function parameters is presented in Table 6. In female rats, alanine aminotransferase (ALT) levels were significantly reduced ($p < 0.05$) in all treatment groups compared with the control group, while aspartate aminotransferase (AST) was significantly reduced in the group administered 250 mg/kg MO seed extract in combination with metformin. In male rats, ALT was significantly reduced in the group administered 1000 mg/kg MO seed extract in combination with metformin ($p < 0.05$) compared with the control group. However, ALP, total protein (TP), and albumin (ALB) did not show significant differences across groups.

Table 6: Effect of 91-day daily administration of *Moringa oleifera* seed extract in combination with metformin on hepatic indices of Wistar Rats

Treatment (mg/kg)	ALT (IU/L)	AST (IU/L)	ALP (IU/L)	TP (g/dL)	ALB(g/dL)
Female					
D/W 1 mL/kg	170.4±2.01	206.2±1.64	164.0±6.78	69.8±1.67	27.4±1.50
MET125	64.0±4.89*	136.0±12.95	221.8±38.75	73.2±3.70	26.8±1.72
MO1000	53.33±1.25*	204.0±5.89	162.3±2.87	74.4±3.06	26.3±1.48
MO250+MET125	27.4±3.77*	97.4±5.35*	132.0±6.53	69.8±3.27	28.4±2.50
MO500+MET125	79.2±7.30*	259.0±40.78	56.0±10.10	78.4±8.20	30.0±1.41
MO1000+MET125	56.5±6.18*	140.3±7.32	139.5±12.82	67.3±2.99	28.5±2.96
Male					
D/W 1 mL/kg	63.5±5.02	213.5±12.87	515.0±56.76	67.3±2.75	31.8±1.92
MET125	51.4±7.74	156.6±11.38	392.4±36.47	66.4±3.36	27.0±1.10
MO1000	53.8±4.38	171.8±10.25	385.0±2.15	67.8±1.70	26.8±1.48
MO250+MET125	60.75±3.16	244.5±2.9	517.5±24.05	64.5±4.12	27.5±2.29
MO500+MET125	52.0±2.16	195.7±10.2	646.3±15.54	64.7±2.08	28.7±1.20
MO1000+MET125	38.5±1.50*	260.5±27.5	475.5±60.5	63.5±0.70	27.0±1.00

Values are mean±SEM; significant changes compared with D/W group using one-way ANOVA followed by Tukey's post hoc test *($p<0.05$). ALT=alanine aminotransferase, AST=aspartate aminotransferase, ALP=alkaline phosphatase, TP=total protein, ALB=albumin, D/W=distilled water, MET125=metformin (125mg/kg) alone, MO1000= *Moringa oleifera* seed extract (1000 mg/kg) alone, MO250+MET125=*Moringa oleifera* seed extract (250 mg/kg) and metformin (125 mg/kg), MO500+MET125=*Moringa oleifera* seed extract (500 mg/kg) and metformin (125 mg/kg), MO1000+MET125= *Moringa oleifera* seed extract (1000 mg/kg) and metformin (125 mg/kg).

Effect of 91-day daily administration of MO seed extract in combination with MET on histo-architecture of kidney and liver

The histo-architecture of the kidney in all groups showed normal histological features such as the glomerulus and tubule in both female and male rats when compared to the control (Figure 2). In the liver, all groups showed normal hepatocytes except the group that was administered

1000 mg/kg MO seed extract in combination with metformin, which showed hepatocyte degeneration (HD) in both male and female rats when compared to the control (Figure 3).

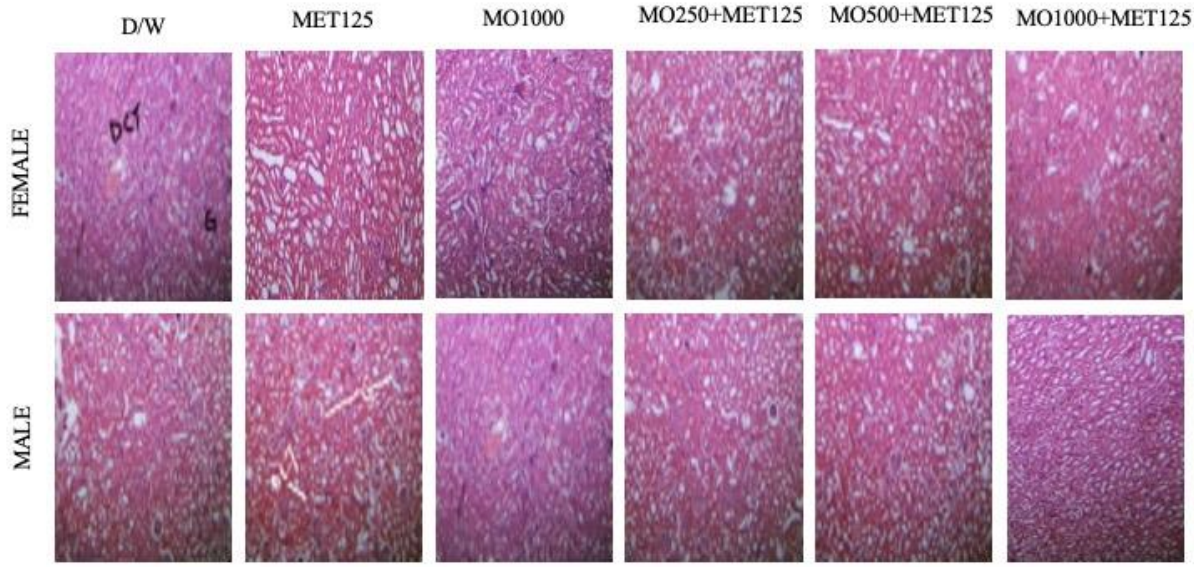

Figure 2: Photomicrograph of the kidney section of rats administered *Moringa oleifera*, metformin and their combination for 91 days
D/W=distilled water, MET125=metformin (125 mg/kg) alone, MO1000= *Moringa oleifera* seed extract (1000 mg/kg) alone, MO250+MET125=*Moringa oleifera* seed extract (250 mg/kg) and metformin (125 mg/kg), MO500+MET125=*Moringa oleifera* seed extract (500 mg/kg) and metformin (125 mg/kg), MO1000+MET125= *Moringa oleifera* seed extract (1000 mg/kg) and metformin (125 mg/kg). (H/E Stain X250).

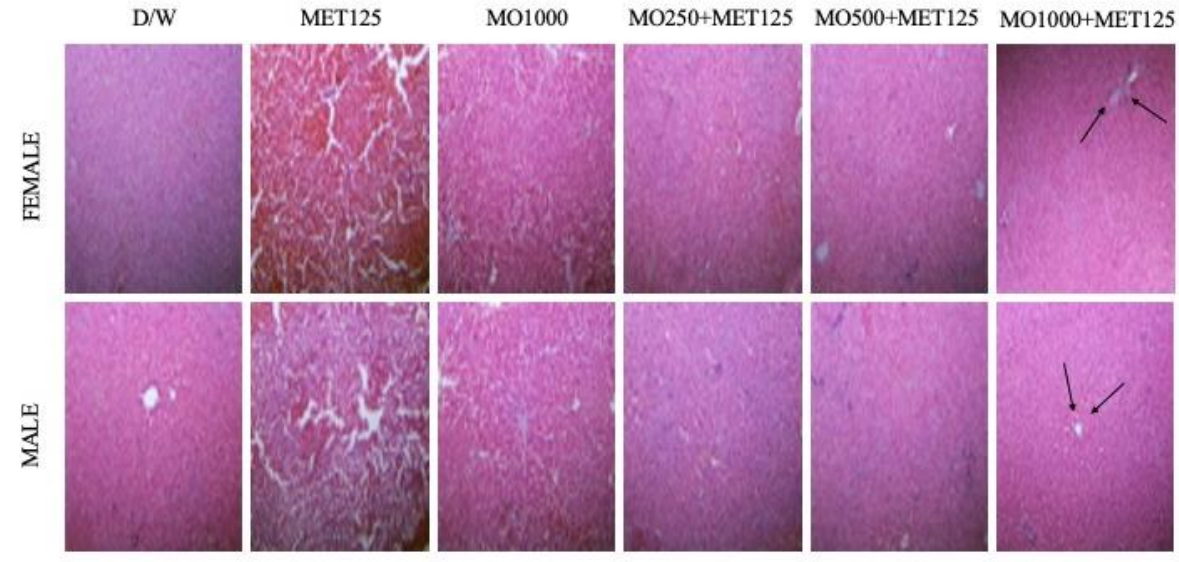

Figure 3: Photomicrograph of the liver section of rats administered *Moringa oleifera*, metformin and their combination for 91 days

D/W=distilled water, MET125=metformin (125 mg/kg) alone, MO1000= *Moringa oleifera* seed extract (1000 mg/kg) alone, MO250+MET125=*Moringa oleifera* seed extract (250 mg/kg) and metformin (125 mg/kg), MO500+MET125=*Moringa oleifera* seed extract (500 mg/kg) and metformin (125 mg/kg), MO1000+MET125= *Moringa oleifera* seed extract (1000 mg/kg) and metformin (125 mg/kg). (H/E Stain X250).

Discussion

Moringa oleifera (MO) seed extract in combination with metformin did not cause clear behavioural abnormalities at the administered doses. In addition, the pattern of deaths did not follow a clear dose-related trend, as mortality occurred across different groups without a steady increase with higher doses. The occurrence of mortality in the distilled water (D/W) control group suggests that factors unrelated to the experimental treatments may have contributed to some of the observed deaths. Possible contributing factors include handling stress, pre-existing health conditions, infection, accidental injury, or other unforeseen experimental conditions. The occurrence of mortality in both sexes indicates that the observed deaths were not exclusively associated with sex; however, the slightly higher mortality observed among females in some treatment groups may indicate a possible difference in susceptibility between sexes.

The food and water intake patterns observed in this study showed only mild and non-consistent fluctuations. This is in line with previous toxicological studies where MO supplementation did not significantly alter feeding or drinking behaviour in rats (Zhang *et al*., 2024). The absence of abnormal intake behaviour also suggests stable metabolic regulation, similar to findings reported in nutritionally supplemented rat models (Rana *et al.,* 2025).

Administration of MO seed extract either alone or in combination with metformin did not result in significant adverse changes in body weight during the 91-day experimental period (Figure 1). The absence of significant body weight loss suggests that the treatments did not induce metabolic dysfunction or reduce feed utilization in the animals. Similar findings have been reported in previous studies where chronic administration of MO extracts did not significantly affect body weight gain in rodents (Leone *et al*., 2015). The maintenance of normal body weight observed in this study may be attributed to the rich nutritional composition of MO, which contains essential amino acids, vitamins, minerals, and antioxidant compounds that may support normal metabolic processes (Islam *et al*., 2021; Bashir *et al*., 2025b).

No variation was observed in relative organ weights. Research on nephroprotective effects of MO has demonstrated that it often preserves renal structure and function even under toxic insult, largely due to its antioxidant and anti-inflammatory properties (Abd elhameed *et al.,* 2025; Meles *et al.,* 2025).

In this study, the haematological indices including hemoglobin (HBG), hematocrit (HCT) and red blood cell count (RBC) did not show significant differences between treated groups and the control group. Maintenance of normal haemoglobin and RBC levels indicates that the treatments did not interfere with erythropoiesis or the oxygen-carrying capacity of blood. These findings suggest that the extract and its combination with metformin did not induce anaemia or haemolysis in the experimental animals. Similar results have been reported in previous toxicological studies in which administration of MO extracts did not significantly affect erythrocyte parameters in rodents (Olayemi *et al*., 2012; Nurhayati *et al*., 2023). The stability of these

haematological indices observed in this study further supports the safety of MO in combination with metformin in sub-chronic exposure conditions. However, a significant difference in white blood cell (WBC) count was observed in both female and male rats treated with the highest dose of MO seed extract alone (Table 4). Alterations in WBC count may indicate activation of immune responses or modulation of inflammatory processes (Chmielewski and Strzelec, 2018; Xiao *et al*., 2020). MO contains various phytochemicals including flavonoids, phenolic acids, and isothiocyanates that have been reported to exhibit immunomodulatory and anti-inflammatory activities (Razis *et al*., 2014). These compounds may stimulate leukocyte production or enhance immune surveillance mechanisms in experimental animals (Xiao *et al*., 2020). Therefore, the observed variation in WBC count in the high-dose group may reflect immunomodulatory activity rather than a toxic effect of the extract. Similar increases in leukocyte counts following administration of MO extracts have been documented in previous studies investigating its immune-enhancing properties (Popoola *et al*., 2020).

The elevated creatinine observed in female rats administered 500 mg/kg MO seed extract in combination with 125 mg/kg metformin (Table 5) may indicate a mild alteration in renal function. However, this finding was observed in only one treatment group and may not necessarily indicate direct nephrotoxicity. Previous studies have generally reported renoprotective effects of M*oringa oleifera* seed preparations in experimental models (Wen *et al*., 2022; Lukiswanto *et al.,* 2023; Rana *et al.,* 2025), while metformin has also demonstrated renal protective properties in some animal studies. This effect was seen in both female and male rats that received 1000 mg/kg MO seed extract in combination with metformin. Low chloride levels were observed in the group administered 1000 mg/kg MO seed extract in combination with metformin, which may indicate an alternation in electrolyte homeostasis. Previous studies have generally reported relatively low toxicity of *M. oleifera* seed preparations at moderate doses, although adverse effects have been observed at higher exposures (Kim *et al*., 2018).

The histopathological observation of normal renal architecture, including intact glomeruli and well-preserved tubules, further supports the biochemical results and agrees with previous studies showing that both MO and metformin do not cause structural kidney damage at doses used. Moringa-based interventions have been shown to preserve renal histoarchitecture and prevent tubular degeneration in toxicological models of kidney injury (Lukiswanto *et al.,* 2023; Meles *et al.,* 2025). Furthermore, studies on gentamicin- and ischemia-induced nephrotoxicity in rats have shown that MO can restore or stabilize kidney histoarchitecture and organ indices, supporting the non-significant changes observed in the present study (Akter *et al.,* 2021; Lukiswanto *et al.,* 2023).

The evaluation of liver function parameters is particularly important in toxicity studies because the liver plays a central role in the metabolism and detoxification of xenobiotics (Serras *et al*., 2021). Alanine aminotransferase (ALT) levels were significantly reduced in most treatment groups compared with the control group (Table 6), particularly among the female rats. ALT is a sensitive biomarker of hepatocellular injury, and elevated levels are commonly associated with liver damage (Ozer *et al*., 2008). The reduction observed in ALT levels in this study may suggest absence of liver injury in the combination groups. Similarly, Aspartate aminotransferase (AST) levels showed a significant reduction in the female group that was administered 250 mg/kg of MO in combination with metformin 125 mg/kg. AST is another important enzyme used in

the evaluation of hepatic integrity, and reductions in its levels may indicate improved liver function or protection against hepatocellular injury (Bashir *et al*., 2024). The antioxidant properties of MO have been shown to reduce lipid peroxidation and stabilize hepatocyte membranes, thereby preventing leakage of intracellular enzymes into the blood (Popoola *et al*., 2020). In addition, metformin has been reported to exert beneficial effects on hepatic metabolism by improving insulin sensitivity and reducing oxidative stress within the liver (Rena *et al*., 2017). Other liver function parameters including Alkaline phosphatase (ALP), Total protein (TP), and Albumin (ALB) did not show significant differences among the treatment groups. These biochemical markers are commonly used to assess hepatic function and biliary tract integrity (Olayemi *et al*., 2012; Nurhayati *et al*., 2023). The absence of significant alterations in these parameters suggests that the treatments did not impair protein synthesis or induce cholestatic liver injury. Albumin and total protein levels are particularly important indicators of liver synthetic capacity, and their stability in this study indicates that hepatic system functional integrity was maintained throughout the experimental period (Popoola *et al*., 2020). However, the group that was administered 1000 mg/kg MO in combination with metformin 125 mg/kg showed hepatocyte degeneration (Figure 3), which may be attributed to the high dose of MO. Other groups showed normal hepatic architecture comparable to the control group. The preservation of normal hepatocyte structure suggests that the treatments did not induce cellular degeneration, necrosis, or inflammatory infiltration in lower doses of MO extract and in combination with metformin. Histological assessment is considered one of the most reliable approaches for confirming biochemical findings in toxicity studies (OECD, 1998). Therefore, the absence of visible pathological lesions in the liver tissues of groups that received a combination of MO seed extract and metformin supports the biochemical evidence indicating that the combination treatments did not cause hepatotoxic effects. Overall, the histological findings of both the liver and kidney did not corroborate the biochemical findings following the 28-day co-administration of MO seed extract with metformin signifying relative non-toxicity in lower combination doses (Bashir *et al*., 2025b).

Conclusion

Based on the findings obtained from this study, it can be concluded that repeated 91-day oral administration of MO seed extract and metformin in combination produced toxic effects due to mortality, hepatocyte degeneration and biochemical changes observed. Thus, combination therapy may require caution.

Aknowledgement

The authors are grateful for the technical assistance of the technologists in the Departments of Pharmacology and Toxicology; Pharmacognosy and Drug Development, Kaduna State University in the present study.

Conflict of interest

The authors declare no conflict of interest in the writing and publication of this manuscript.

References

Abd elhameed E, Halim Z, Adel M, Abd El-Hamed A and Messiha R (2025). Effect of n-acetyl cysteine and moringa oleifera on acute kidney injury induced by cisplatin in rats. Bulletin of Egyptian Society for Physiological Sciences, 45(4):532-549. https://doi.org/10.21608/besps.2025.383383.1214

Abubakar A, Nazifi AB, Hassan FI, Duke KA and Edoh TD (2019). Safety

assessment of *Chlorophytum alismifolium* tuber extract (Liliaceae): Acute and sub-acute toxicity studies in Wistar rats. Journal of Acute Disease, 8(1):21-27. https://doi.org/10.4103/2221-6189.250374

Abubakar A, Nazifi AB, Abdulazeez J, Abubakar AZ, Maje IM, Tanko Y, ... and Abdurahman EM (2023). Repeated dose 13-week oral toxicity evaluation of *Chlorophytum alismifolium* Baker methanol extract in Wistar rats. Comparative Clinical Pathology, 32(3):413-425 https://doi.org/10.1007/s00580-023-03451-823

Abdulhakim A, Balarabe NA, Obeid MA, Wemimo A, Lawal AF, Wahab K and Adesokan AM (2025). Preclinical toxicological evaluation of adjunct dementia medicinal supplement (PMCV002) in Wistar rats: from bench to clinical trial series. Therapeutic Delivery, 16(9): 853-861. https://doi.org/10.1080/20415990.2025.2545748

Akter T, Rahman MA, Moni A, Apu MAI, Fariha A, Hannan MA and Uddin MJ (2021). Prospects for Protective Potential of *Moringa oleifera* against Kidney Diseases. Plants, 10(12):2818. https://doi.org/10.3390/plants10122818

Arthur SJ and John B (1978). A colour atlas of histopathological staining techniques. Wolfer Medical Publishers, Ltd., London, pp 14-20

Bartels H, Böhmer M and Heierli C (1972). Serum creatinine determination without protein precipitation. Clinica chimica Acta; International Journal of Clinical Chemistry, 37:193-197. https://doi.org/10.1016/0009-8981(72)90432-9

Bashir A-J, Isa KA, Danbala AA and Borodo SB (2025a). Acute antihyperglycaemic effect of the combination of metformin and ethanol extract of *Moringa oleifera* Lam. in rats. Trends in Natural Products Research, 6(1), 45–53. https://doi.org/10.61594/tnpr.v6i1.2025.120

Bashir AIJ, Ahmed ZI, Nuhu H, Umar F, Yakubu MI and Jimoh AA (2025b). Sub-Chronic Toxicity Study of Ethanol Seed Extract of *Moringa oleifera* Lam. Combination with Metformin in Rats. Dutse Journal of Pure and Applied Sciences (DUJOPAS), 11(2c): 176-190. https://www.ajol.info/index.php/dujopas/article/view/299801

Bashir F, Sharif S, Manzoor F, Naz S and Rashid F (2024). Protective Effects of *Moringa oleifera* Leaf Extract against Silver Nanoparticles and Arsenic Induced Hepatotoxicity in Rats. Pakistan Veterinary Journal, 44(2). https://doi.org/10.29261/pakvetj/2024.154

Belfield A and Goldberg DM (1971). Revised assay for serum phenyl phosphatase activity using 4-amino-antipyrine. Enzyme, 12(5):561–573. https://doi.org/10.1159/000459586

Chaachouay N (2025). Synergy, additive effects, and antagonism of drugs with plant bioactive compounds. Drugs and Drug Candidates, 4(1):4. https://doi.org/10.3390/ddc4010004

Chmielewski PP and Strzelec BJFM (2018). Elevated leukocyte count as a harbinger of systemic inflammation, disease progression, and poor prognosis: a review. Folia morphologica, 77(2):171-178. https://doi.org/10.5603/FM.a2017.0101

Doumas BT, Watson WA and Biggs HG (1971). Albumin standards and the

measurement of serum albumin with bromcresol green. Clinica Chimica Acta, 31(1):87–96. https://doi.org/10.1016/0009-8981(71)90365-2

Ebadi AG (2025). Synergistic Approaches in Diabetes Management: The Role of Anti-Diabetic Drugs and Herbal Medicine in Therapeutic Strategies. Nepal Journal of Medical Sciences, 10(2):68–82. https://doi.org/10.3126/njms.v10i2.79012

Islam Z, Islam SMR, Hossen F, Mahtab-ul-Islam K, Hasan MdR, Karim R (2021). *Moringa oleifera* is a Prominent Source of Nutrients with Potential Health Benefits, International Journal of Food Science, 6627265:11. https://doi.org/10.1155/2021/6627265

Izah SC, Ogidi OI, Ogwu MC, Salimon SS, Yusuf ZM, Akram M, Raimi MO and Iyingiala A-A (2024). Historical Perspectives and Overview of the Value of Herbal Medicine. Herbal Medicine Phytochemistry. Reference Series in Phytochemistry. Springer, Cham. https://doi.org/10.1007/978-3-031-43199-9_1

Kim Y, Jaja-Chimedza A, Merrill D, Mendes O and Raskin I (2018). A 14-day repeated-dose oral toxicological evaluation of an isothiocyanate-enriched hydro-alcoholic extract from *Moringa oleifera* Lam. seeds in rats. Toxicology Reports, 5:418–426. https://doi.org/10.1016/j.toxrep.2018.02.012

Kumar AH and Clover AJ (2015). Intraperitoneal co-administration of low dose urethane with xylazine and ketamine for extended duration of surgical anesthesia in rats. Laboratory Animal Research, 31(4):174–179. https://doi.org/10.5625/lar.2015.31.4.174

Leone A, Spada A, Battezzati A, Schiraldi A, Aristil J, Bertoli S (2015). Cultivation, Genetic, Ethnopharmacology, Phytochemistry and Pharmacology of *Moringa oleifera* Leaves: An Overview. International Journal of Molecular Sciences, 16(6):12791-12835. https://doi.org/10.3390/ijms160612791

Lukiswanto BS, Wijayanti H, Fadhila Y, Yuniarti W, Arimbi A, Suprihati E and Kurnijasanti R (2023). Protective effect of Moringa oleifera leaves extract against gentamicin induced hepatic and nephrotoxicity in rats. Iraqi Journal of Veterinary Sciences, 37(1), 129-135. https://doi.org/10.33899/ijvs.2022.133276.2197

Meles DK, Mustofa I, Wurlina W, Rosyada ZNA, Khairullah AR, Rachmawati K, Hidayah AN, Suwasanti N, Mustofa RI, Akintunde AO, Ahmad RZ, Ekawasti F, Riwu KHP and Riwu AG (2025). Impact of *Moringa oleifera* leaf extract on renal histopathology, malondialdehyde, superoxide dismutase, and calcium oxalate crystals in rats (*Rattus norvegicus*) exposed to ethylene glycol. Open Veterinary Journal, 15(4):1734-1746. https://doi.org/10.5455/OVJ.2025.v15.i4.25

Nurhayati T, Fathoni MI, Fatimah SN, Tarawan VM, Goenawan H and Dwiwina RG (2023). Effect of *Moringa oleifera* Leaf Powder on Haematological Profile of Male Wistar Rats. Journal of Blood Medicine, 14:477–485. https://doi.org/10.2147/JBM.S407884

Nurhayati T, Ridho MF, Santoso PTR, Setiawan S, Goenawan H and Tarawan VM (2024). Effects of *Moringa oleifera* Leaf Extract on Liver Histopathology: A Systematic Review. Journal of Nutrition and Metabolism, 6815993:15. https://doi.org/10.1155/2024/6815993

OECD (1998). Guidelines for the testing of chemicals: Repeated dose 90-day oral

toxicity study in rodents (OECD Test Guideline 408). Organisation for Economic Co-operation and Development. https://doi.org/10.1787/9789264070707-en

Olayemi FO and Arowolo RO (2012). The haematological and biochemical effects of methanol extract of the seeds of *Moringa oleifera* in rats. Journal of Medicinal Plants Research, 6(4):615-621. http://www.academicjournals.org/JMPR

Ozer J, Ratner M, Shaw M, Bailey W and Schomaker S (2008). The current state of serum biomarkers of hepatotoxicity. Toxicology, 245(3):194-205. https://doi.org/10.1016/j.tox.2007.11.021

Pareek A, Pant M, Gupta MM, Kashania P, Ratan Y, Jain V, Pareek A, Chuturgoon AA. (2023). *Moringa oleifera*: An Updated Comprehensive Review of Its Pharmacological Activities, Ethnomedicinal, Phytopharmaceutical Formulation, Clinical, Phytochemical, and Toxicological Aspects. International Journal of Molecular Sciences, 24(3):2098. https://doi.org/10.3390/ijms24032098

Popoola JO, Aworunse OS, Oyesola LO, Akinnola OO, Obembe OO (2020). A systematic review of pharmacological activities and safety of *Moringa oleifera*. Journal of Herbmed Pharmacology, 9(3):174-190. https://doi.org/10.34172/jhp.2020.24

Rana KP, Mangroliya P, Das B and Mugale A (2025). Pharmacological and Nutritional Value of Moringa Oleifera: A Comprehensive Review of Its Role as a Food and Medicine. European Journal of Medicinal Plants, 36(3):106–117. https://doi.org/10.9734/ejmp/2025/v36i31266

Razis AFA, Ibrahim MD and Kntayya SB (2014). Health Benefits of *Moringa oleifera*. Asian Pacific Journal of Cancer Prevention, 15(20):8571-8576. http://dx.doi.org/10.7314/APJCP.2014.15.20.8571

Reitman S and Frankel S (1957). A colorimetric method for the determination of serum glutamic oxalacetic and glutamic pyruvic transaminases. American Journal of Clinical Pathology, 28(1):56–63. http://doi.org/10.1093/ajcp/28.1.5625

Rena G, Hardie DG and Pearson ER (2017). The mechanisms of action of metformin. *Diabetologia, 60*(9), 1577–1585. https://doi.org/10.1007/s00125-017-4342-z

Serras AS, Rodrigues JS, Cipriano M, Rodrigues AV, Oliveira NG and Miranda JP (2021). A Critical Perspective on 3D Liver Models for Drug Metabolism and Toxicology Studies. Front. Cell Dev. Biol., 9:626805. https://doi.org/10.3389/fcell.2021.626805

Walters MI and Gerarde HW (1970). An ultramicromethod for the determination of conjugated and total bilirubin in serum or plasma. Microchemical Journal, 15(2):231–243. https://doi.org/10.1016/0026-265X(70)90045-7

Weatherburn M (1976). Phenol-hypochlorite reaction for determination of ammonia. Analytical Chemistry, 39(8):971–974. https://doi.org/10.1021/ac602 52a045

Wen Y, Liu Y, Huang Q, Liu R, Liu J, Zhang F, Liu S and Jiang Y (2022). *Moringa oleifera* Lam. seed extract protects kidney function in rats with diabetic nephropathy by increasing GSK-3β activity and activating the Nrf2/HO-1 pathway. Phytomedicine, 95:153856. https://doi.org/10.1016/j.phymed.2021.153856

Xiao X, Wang J, Meng C, Liang W, Wang T, Zhou B, Wang Y, Luo X, Gao L and Zhang L (2020). *Moringa oleifera* Lam and its Therapeutic Effects in Immune Disorders. Frontiers in Pharmacology, 11:566783. https://doi.org/10.3389/fphar.2020.566783

Zhang YW, Wang FJ, Cai M *et al.* (2024). Evaluation of the feeding safety of Moringa (*Moringa oleifera* L.) in the Sprague Dawley rat. Sci Rep, 14:10647. https://doi.org/10.1038/s41598-024-51442-8

Zhou H, Zhang M, Cao H, Du X, Zhang X, Wang J and Bi X (2023). Research progress on the synergistic anti-tumor effect of natural anti-tumor components of Chinese herbal medicine combined with chemotherapy drugs. Pharmaceuticals, 16(12):1734. https://doi.org/10.3390/ph16121734