Hepatoprotective activity of ethanol root extract and fractions of *Hippocratea africana* against doxorubicin-induced liver toxicity

Kufre U. Noah[1], John A. Udobang[2], Joseph Oyepata Simeon[3,]*Jude E. Okokon[1],

1. Department of Pharmacology and Toxicology, Faculty of Pharmacy, University of Uyo, Uyo, Nigeria.
2. Department of Clinical Pharmacology and Therapeutics, Faculty of Basic Clinical Sciences, University of Uyo, Uyo, Nigeria.
3. Department of Pharmacology and Toxicology, Faculty of Pharmacy, Federal University Oye Ekiti, Ekiti State, Nigeria.

Submitted: 9th July., 2023; Accepted: 10th August., 2023; Published online: 31st Aug., 2023
DOI: https://doi.org/10.54117/jcbr.v3i4.6
**Corresponding Author: Jude E. Okokon; judeefiom@yahoo.com; +234-8023453678*

Abstract

Doxorubicin (DOX) is an anthracycline glycoside antibiotic with high efficacy against various forms of cancer, whose clinical usefulness has been limited by associated undesirable organs toxicities such as cardiomyopathy, nephrotoxicity and hepatotoxicity despite its high therapeutic index. *Hippocratea africana* root used locally in the treatment of poisoning was evaluated for antidotal potentials against DOX-induced liver toxicity in rats. *Hippocratea africana* ethanol root extract as well as dichloromethane and aqueous fractions were evaluated for hepatoprotective activity against doxorubicin-induced liver injury in rats at various doses of the crude extract (200-600 mg/kg) and 400 mg/kg each of dichloromethane (DCM) and aqueous fractions respectively. Liver function parameters, liver oxidative stress markers and liver histology were used to assess the liver protective potential of the extract and fractions. The root extract and fractions significantly ($p<0.05$-0.01) reduced the serum levels of AST, ALT, ALP, total and direct bilirubin that were elevated by doxorubincin. Also, the levels of total protein and albumin reduced by doxorubicin were increased by the extract coadministration. The levels of GSH, GST, SOD, GPx, and CAT that were decreased by doxorubicin were significantly ($p<0.01$) elevated and raised MDA level was reduced by the leaf extract. Histology of the liver sections of extract -treated animals showed reductions in the pathological features compared to the DOX-treated animals. The observed histopathological changes were consistent with chemical pathological observations suggesting marked hepatoprotective potential. The anti-toxic effect of this plant may in part be mediated through the chemical constituents of the plant. The plant, *Hippocratea africana* possesses anti-toxicant properties which can be exploited in the treatment of doxorubicin related toxicities.

Keywords: ***Hippocratea africana*, anti-toxicant, antioxidative stress, hepatoprotective, antioxidant**

Introduction

Hippocratea africana (Willd.) Loes. ex Engl. (Celastraceae) known in English as African paddle-pod and Eba enang enang' in Ibibio language in Nigeria, is a climber perennial plant distributed widely in tropical Africa (Hutchison and Dalziel, 1973). Traditionally, the plant root has been variously utilized in herbal preparations to treat diseases like malaria and diabetes (Okokon *et al.*, 2006), as well as liver diseases (Ajibesin *et al.*, 2008). Previous reports showed that the root extract possess antimalarial (Okokon *et al.,* 2006;2021), antioedema and antinociceptive (Okokon *et al.,* 2008), antidiabetic and hypolipidemic (Okokon *et al.*, 2010; 2022), antidiarrhoeal and antiulcer (Okokon *et al.,* 2011), hepatoprotective (Okokon *et al.,* 2013a), antileishmanial, cytotoxicity and cellular antioxidant (Okokon *et al.*, 2013b), antibacterial, anticonvulsant and depressant (Okokon *et al.,* 2014). Also, earlier studies had reported the presence of $^{\delta}$-3-carene and α-terpineol (Okokon *et al.,* 2017), and the isolation of 1,3,7-trihydroxy-6-methoxyxanthone [isoathyriol] and 1,3,6,7-tetrahydroxyxanthone [norathyriol] (Umoh *et al.*, 2021) from ethyl acetate fraction. Monoterpenes and sesquiterpenes have been identified in the *n*-hexane fraction (Okokon *et al.,* 2013a). We report hepatoprotective and antioxidative stress effects of the root extract and fractions of *H. africana* against doxorubicin-induced hepatotoxicity in rats.

Materials and Methods

Plants collection

Fresh roots of *Hippocratea africana* were collected in bushes in Uruan area, Akwa Ibom State, Nigeria in November, 2021. The plant was identified and authenticated by a taxonomist, Prof Margaret Bassey in

the Department of Botany and Ecological Studies, University of Uyo, Uyo, Nigeria. Hebarium specimen (UUPHB 30(i)) was deposited at Department of Pharmacognosy and Natural Medicine Herbarium, University of Uyo.

Preparation of extract and fractions

Hippocratea africana roots were cut into smaller pieces, rinsed, and dried for two weeks in the shade. They were ground into powder using an electric grinder. *H. africana* (HAE) root powder was steeped in 50% ethanol for 72 hours. The resulting liquid filtrate was concentrated at 40 °C in a rotary evaporator. To get DCM and aqueous fractions, the crude extract (20 g) was dispersed in 500 mL of distilled water and partitioned with an equivalent volume of dichloromethane (DCM), 5 x 500 mL, until no color change was noticed. Until the experiment, the extract and fractions were kept in a refrigerator at 4 °C.

Animals

Male albino Wistar rats were used in this study. The animals were housed in plastic cages and obtained from the University of Uyo Animal House. Rats were provided unlimited access to water and fed on pelleted standard Feed (guinea feed). The College of Health Sciences Animal Ethics Committee at the University of Uyo gave its approval to the project (UU/FP/AE/22/055).

Experimental design

In this study, a 14-day repeated dose model described by Raskovi *et al.* (2011) and Olorundare *et al*. (2020), was used. Groups I rats which served as the untreated control were orally pretreated with 10 mL/kg/day of distilled water. Group 2 rats were given normal saline (10 mL/kg/day) but equally treated on alternate days with 1.66 mg/kg of doxorubicin hydrochloride dissolved in 0.9% normal saline administered on alternate days for 14 days. Groups 3-5 rats were orally pretreated daily with 200 mg/kg/day, 400 mg/kg/day,

and 600 mg/kg/day of *Hippocratea africana* dissolved in distilled water respectively. Groups 6 and 7 were pretreated daily with 400 mg/kg of DCM and aqueous fractions respectively. Two hours after treatments, 1.66 mg/kg of doxorubicin in 0.9% normal saline was administered intraperitoneally to each extract-treated group on alternate days for 14 days. Group 8, the positive control group, were equally pretreated daily with 100 mg/kg/day of silymarin two hours before intraperitoneal administration of 1.66 mg/kg of doxorubicin in 0.9% normal saline on every other day for 14 days.

Collection of blood samples and organs

After 14 days of treatment (24 hours after the last administration), the rats were weighed again and sacrificed under light diethyl ether vapour. Blood samples were collected by cardiac puncture and used immediately. Blood samples were collected into plain centrifuge tubes, centrifuged at 2500 rpm for 15 mins to separate the serum at room temperature and stored at -20°C until used for biochemical determinations. The livers of the rats were surgically removed, weighed, gently and carefully divided into two parts; a part was fixed in 10 % formaldehyde for histological processes, while the other part of the liver was briskly rinsed in ice cold 1.15% KCl solution and put in a clean sample bottle. These were stored in ice cold 0.9% NaCl.

Assessment of the effect of extract on liver function parameters of rats

The collected serum was used to determine total protein, albumin, total and direct bilirubin, aspartate aminotransferase (AST), alanine aminotransferase (ALT), alkaline phosphotase (ALP), and total cholesterol. All biochemical parameters were computed at the University of Uyo Teaching Hospital using automated analyzers and Fortress Diagnostic Kits®

(Fortress Diagnostic Limited, UK) in line with manufacturer's guideline.

Oxidative Stress Markers

Preparation of liver Homogenate

Liver homogenates were made in a ratio of 1 g of wet tissue to 9 ml of 1.25% KCl by using motor driven Teflon-pestle. The homogenates were centrifuged at 7000 rpm for 10 min at 4˚C and the supernatants were used for the assays of superoxide dismutase (SOD) (Marklund and Marklund, 1974), catalase (CAT) (Sinha,1972), glutathione peroxidase (GPx) (Lawrence and Burk,1976), reduced gluthathione (GSH) (Ellman,1959) and malondialdehyde (MDA) content (Esterbauer and Cheeseman, 1990). The assays were performed on testes homogenates of rats that were used in this study. These oxidative stress markers were used to assess antioxidative stress potentials of the extract.

Histopathological studies

For histological procedures, excised liver that had been fixed in 10% buffered formalin was employed. According to established protocols, they were processed and stained with haematoxylin and eosin (H&E) at the Department of Chemical Pathology, University of Uyo Teaching Hospital, Uyo (Drury and Wallington, 1980). The organs were inspected for morphological changes under the microscope at x400. Micrographs were taken of histologic images.

Statistical analysis

Data collected were analysed using one way analysis of variance (ANOVA) followed by Tukey's multiple comparison post-test (Graph pad prism software Inc. La Jolla, CA, USA). Values were expressed as mean ± SEM and significance relative to control were considered at $p<0.001$ and $p<0.05$.

Results

Effect of root extract and fractions of *H. africana* on body and organs weights of rats with doxorubicin-induced toxicity

Administration of *H. africana* root extract and fractions to rats with doxorubicin-induced organs toxicities caused considerable improvement of the body weights compared to the untreated group. The crude extract caused a significant ($p<0.01$) dose-dependent effect when compared to the untreated group with the dichloromethane fraction treated group exerting the highest effect. The weights of the organs (liver, kidney, heart and testis) of the group treated with doxorubicin only were found to be reduced when compared to those of the normal control group though not statistically significant ($p>0.05$). However, treatment of rats with doxorubicin-induced toxicities with the root extract and fractions of *H. africana* improved the organs weights which was not significant ($p>0.05$) when compared to that of the doxorubicin only group (Table 1).

Table 1: Effect of *H. africana* root extract on body and liver weights of rats with doxorubicin-induced toxicity

PARAMETERS/ TREATMENT	Dose mg/kg	Liver	Body weight		
			Before	After	% increase in body weight
Normal control	-	6.76±0.59	135.6±18.34	151.0± 12.33	11.35
Doxorubicin	1.66	8.08±0.71	130.0 ± 9.45	126.3± 10.43	-2.84
Silymarin+DOX	100	7.09±1.31	132.6± 14.55	143.2 ± 3.15	7.99
Extract+DOX	200	6.47±0.87	142.8± 10.56	153.0± 5.29	7.14
	400	7.79±0.11	140.3± 7.36	151.6 ± 6.22	8.05

	600	6.73±0.99	138.4 ± 8.54	149.6 ± 8.48	8.09
Aqueous fraction	400	6.49±0.54	138.4 ± 6.26	144.6± 10.22	4.47
DCM fraction	400	6.82±0.60	134.3± 8.50	146.8± 13.20	9.30

Data were expressed as mean ±SEM. Not significant at $p<0.05$ when compared to normal control and Dox-only control control. n = 6.

Effect of root extract and fraction on liver function parameters of rats with doxorubicin-induced hepatotoxicity

There was a significant ($p<0.001$) elevation in the levels of AST, ALT, ALP, total and combined bilirubin and decreases in total protein and albumin levels when compared to control in doxorubicin-only group. Concomitant administration of root extract and fractions (200-600 mg/kg) with doxorubicin caused significant ($p<0.05$-0.001) non dose-dependent reductions in AST, ALT, ALP levels and the level of combined bilirubin in the extract/fractions-treated groups when compared with the untreated group; with the aqueous fraction exerting the highest reduction. Also, non-significant ($p>0.05$) reduction was also observed in the level of total bilirubin in the extract/fractions-treated groups. Total protein and albumin levels were significantly ($p<0.05$-0.001) elevated non dose-dependently in the extract/fractions - treated groups when compared to the doxorubicin-only group (Table 2).

Effect of root extract and fraction on liver oxidative stress markers of doxorubicin-induced liver toxicity.

Table 3 shows the effect of the root extract/fractions on liver oxidative stress markers of the rats. Administration of doxorubicin alone to group 2 animals caused significant ($p<0.01$-0.001) decrease in liver antioxidant enzymes activities (SOD, GPx, GST, CAT) and GSH levels when compared to control. The MDA level

was also elevated by doxorubicin treatment. However, concomitant administration of the extract/fractions (200- 600 mg/kg) with doxorubicin caused significant ($p<0.05$-0.001) and non-dose dependent elevations of the enzymatic and non enzymatic endogenous antioxidants in the treated rats groups when compared to the untreated groups, with the highest dose (600 mg/kg) and DCM fraction producing higher increases. Dose-dependent and significant ($p<0.05$) decreases in MDA levels of the extract/fractions treated groups were observed. Similar decrease was also observed in the silymarin-treated group when compared to Dox-only control (Table 3).

Table 2: Effect of *H.africana* root extract and fractions on liver function parameters of rats with doxorubicin-induced toxicity

Treatment	Dose mg/kg	Total protein (g/ dL)	Albumin (g/dL)	Total Bilirubin (µmol/L)	ALT (U/L)	ALP (U/L)	AST (U/L)	Combined Bilirubin (µmol/L)
Control	10	68.0± 2.85	40.25±1.79	5.07±0.42	18.20± 1.12	37.0± 3.58	24.0± 1.91	2.52± 0.20
Doxorubicin	1.66	51.33± 2.40^{c}	31.66±1.76^{d}	8.10±0.60^{e}	25.50± 0.36^{c}	63.66± 6.00^{c}	39.0± 0.53^{c}	5.41± 0.58^{f}
Crude extract	200	71.66±3.52^{f}	44.33± 2.33e	5.73±0.95	12.33± 0.77^{f}	49.33±3.38	29.33± 0.76^{f}	3.68± 0.60^{d}
	400	79.33±0.66^{f}	47.33±0.33^{f}	5.80±0.45	11.46± 0.14^{f}	39.33± 4.33^{e}	28.66± 0.88^{f}	3.30± 0.11^{e}
	600	61.66±0.88^{d}	41.33± 1.20^{d}	6.23±0.14	13.90± 0.83^{f}	42.66± 0.88^{d}	29.66± 0.88^{f}	3.60± 0.26^{d}
Aqueous Fraction	400	58.25±1.37^{a}	34.50±1.32	6.80±0.28	14.25± 0.39^{f}	38.0± 1.95^{f}	33.75± 1.28^{e}	3.92± 0.26^{d}
DCM fraction	400	56.66±2.02	35.33±1.45	7.36±0.42^{a}	9.96± 1.41^{f}	42.0± 1.73^{e}	35.66± 1.33^{e}	4.50 ± 0.11^{d}
Silymarin	100	61.66±2.02	38.66±1.85	5.50±0.46^{d}	8.03± 1.41^{a,f}	37.0± 3.05^{f}	27.33± 1.02^{f}	3.20± 0.32^{e}

Data is expressed as MEAN ± SEM, Significant at $^{a}p<0.05$, $^{b}p<0.01$, $^{c}p<0.001$, when compared to control; Significant at $^{d}p<0.05$, $^{e}p<0.01$, $^{f}p<0.001$ compared to Dox-only control group. (n=6)

Table 3: Effect of *H.africana* root extract and fractions on liver oxidative stress markers of rats with doxorubicin-induced toxicity

Treatment	Dose mg/kg	SOD (U/ml)	CAT (U/g of protein)	GPx (µg/ml)	GSH (µg/ml)	GST	MDA (µMol/ml)
Control	10	0.41±0.01	4.25±0.01	0.065±0.001	1.20±0.01	0.42±0.01	0.25±0.01
Doxorubicin	1.66	0.20±0.001^{b}	1.15± 0.01^{c}	0.024±0.001^{c}	0.43±0.01^{b}	0.23±0.01^{b}	0.71±0.01^{c}
Crude extract	200	0.26±0.01^{b}	2.41±0.25^{b,d}	0.033±0.001^{a,d}	1.16± 0.05^{e}	0.39±0.01^{e}	0.50±0.01^{b}
	400	0.31±0.02^{d}	1.94±0.10^{c}	0.049±0.001^{f}	1.19± 0.01^{d}	0.32±0.01^{a,d}	0.46±0.03^{d}
	600	0.35±0.02^{e}	3.43± 0.15^{f}	0.055±0.003^{f}	1.18± 0.02^{e}	0.34±0.01^{e}	0.41±0.02^{d}
Aqueous Fraction	400	0.22±0.01^{b}	2.05±0.02^{b}	0.040±0.002^{e}	1.07± 0.03^{d}	0.28±0.05^{a}	0.51± 0.01^{b}
DCM fraction	400	0.36±0.01^{d}	2.36±0.12^{a,d}	0.061±0.001^{f}	1.11± 0.01^{e}	0.39±0.02^{e}	0.45± 0.01^{d}
Silymarin	100	0.33±0.05^{d}	3.02±0.11^{a,e}	0.064±0.02^{f}	1.17±0.02^{e}	0.40±0.03^{e}	0.42±0.06^{d}

Data is expressed as MEAN ± SEM, Significant at [a]p<0.05, [b]p<0.01, [c]p<0.001, when compared to control;Significant at [d]p<0.05, [e]p<0.01, [f]p<0.001 compared to Dox-only control group.. (n=6

Effect of root extract and fractions of *H. africana* on histology of rat liver in doxorubicin-induced hepatotoxicity

Histologic sections of livers of rats receiving various treatments at magnification (x400) stained with H&E method revealed that normal control had lobular architecture of the liver with normal hepatocytes (arrows) and average-sized central veins (CV) and sinusoid (arrow head). No pathological changes were seen. The doxorubicin alone group had parenchymal showing arrays of distorted hepatocytes (arrow) with widely spread cytoplasmic vacuolation when compared to control group (Figure 1), depicting pathological changes. Also, average-sized central vein and bile ducts of the portal triad were observed. Group 3 (C), which was treated with 200 mg/kg of *H.africana* root extract and doxorubicin showed lobular architecture of the liver with normal hepatocytes and averaged sized central vein and sinusoid. No pathological sign was observed. Group 4 (D), treated with 400 mg/kg of *H.africana* root extract and doxorubicin showed a lobular architecture of the liver with normal hepatocytes and average-sized central veins and sinusoid. Focal fatty changes were seen. Group 5 (E), treated with 600 mg/kg of *H. africana* root extract and doxorubicin showed arrays of hepatocytes of which some showed cytoplasmic vacuolation. The blood vessels and the sinusoidal spaces were average in size. Rats treated with aqueous fraction (400 mg/kg) of *H. africana* root and doxorubicin in group 6 (F), had liver section that revealed a lobular architecture of the liver with normal hepatocytes and average-sized central veins and sinusoid with no visible morphological changes. Liver section of group 7 (G) rats treated with dichloromethane fraction and doxorubicin showed lobular architecture of the liver

with normal hepatocytes and averaged sized central vein and sinusoid. No abnormality was observed. The silymarin (100 mg/kg) and doxorubicin treated rats in group 8 (H) had liver section that showed lobular architecture of the liver with normal hepatocytes and average-sized central veins) and sinusoid with no visible morphological changes (Figure 1)

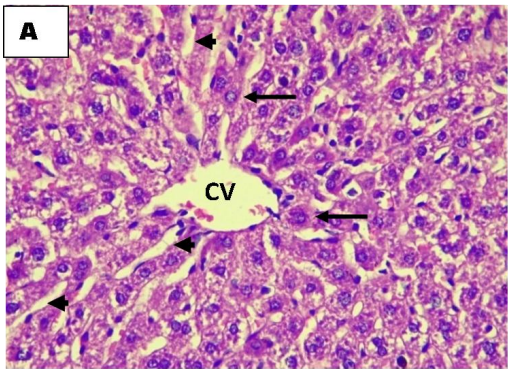

Figure 1A: Histological liver section of rat treated with distilled water (10mL/kg) showing lobular architecture of the liver with normal hepatocytes (arrows) and average-sized central veins (CV) and sinusoid (arrow head). No pathological changes seen. H&E Stain, x400 magnification

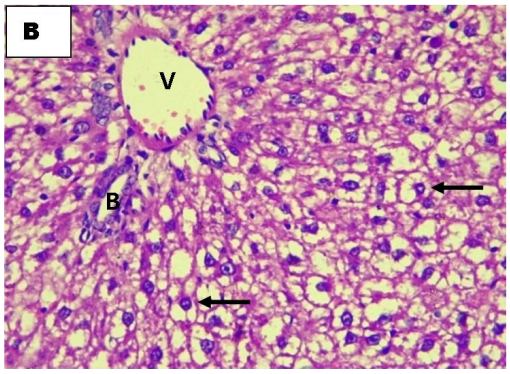

Figure 1B: Histological liver section of rat treated with doxorubicin (1.66 mg/kg) showing average-sized blood vessels (V) and bile ducts (B) of the portal triad. The parenchymal showed arrays of hepatocytes (arrow) with widely spread cytoplasmic vacuolation. H&E Stain, x400 magnification

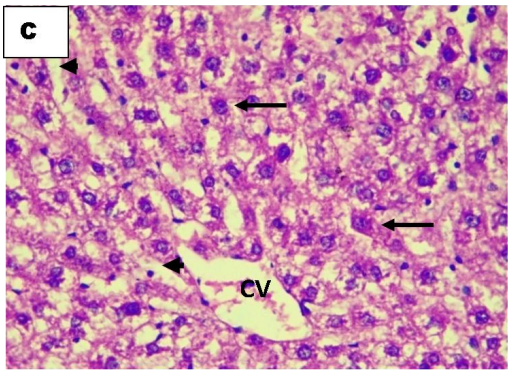

Figure 1C: Histological liver section of rat treated with 200mg/kg of *H.africana* root extract and doxorubicin (1.66mg/kg) showing lobular architecture of the liver with normal hepatocytes (arrows) and averaged sized central vein (CV) and sinusoid (arrow head). (H&E Stain) x400 magnification.

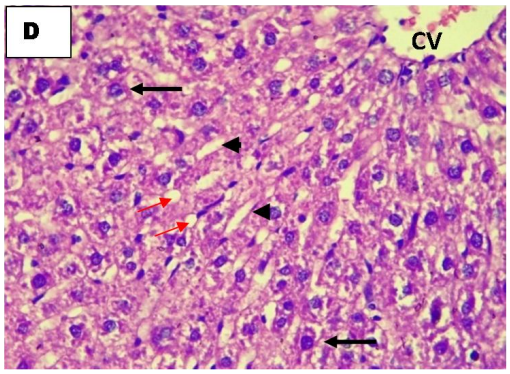

Figure 1D: Photomicrograph of liver section of rat treated with 400mg/kg of *H.africana* root extract and doxorubicin (1.66mg/kg) showing the lobular architecture of the liver with normal hepatocytes (arrows) and average-sized central veins (CV) and sinusoid (arrow head). There are focal fatty changes (red thin arrow). H&E Stain, x400 magnification

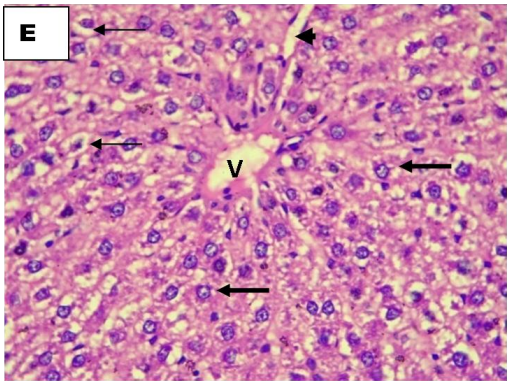

Figure 1E: Photomicrograph of the liver section of rat treated with 600mg/kg of *H.africana* root extract and doxorubicin (1.66mg/kg) showed arrays of hepatocytes (thick arrow) of which some showed cytoplasmic vacuolation (thin arrow). The blood vessels (V) and the sinusoidal spaces (arrowhead) are average in size. H&E Stain, x400 magnification

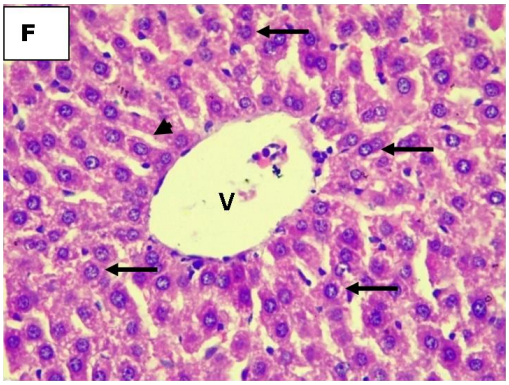

Figure 1 F: Photomicrograph of liver section of rat treated with aqueous fraction (400mg/kg) of *H. africana* root and doxorubicin (1.66mg/kg) showing the lobular architecture of the liver with normal hepatocytes (arrows) and average-sized central veins (CV) and sinusoid (arrow head). No pathological changes seen. H&E Stain, x400 magnification

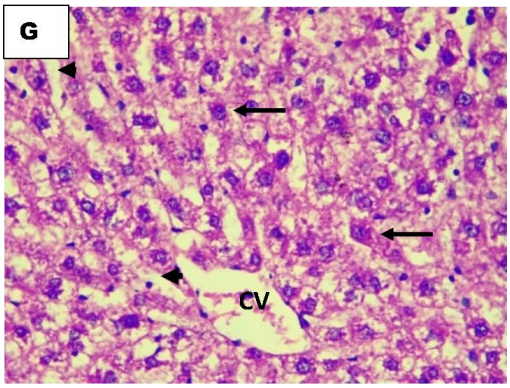

Figure 1G: Photomicrograph of liver section of rat treated with dichloromethane fraction (400mg/kg) of *H.africana* root and doxorubicin (1.66mg/kg) showing lobular architecture of the liver with normal hepatocytes (arrows) and averaged sized central vein (CV) and sinusoid (arrow head). Haematoxylin and Eosin Stain (H&E Stain) x400 magnification.

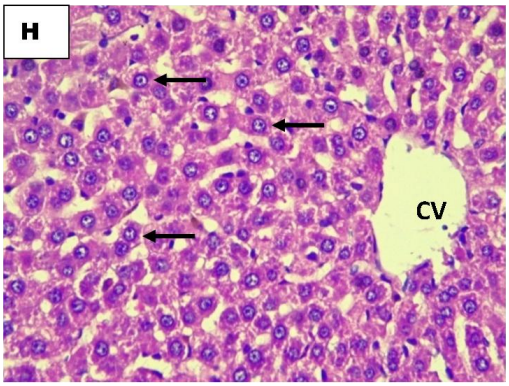

Figure 1 H: Photomicrograph of liver section of rat treated with silymarin (100mg/kg) and doxorubicin (1.66mg/kg) It showed the lobular architecture of the liver with normal hepatocytes (arrows) and average-sized central veins (CV) and sinusoid (arrow head). No pathological changes seen. H&E Stain, x400 magnification

Discussion

Doxorubicin administration was found to have increased the liver weights of treated rats significantly, while co-administration of the root extract and fractions to rats counteracted this increase and caused significant decrease in weights of livers of treated rats. Internal organs weights are often used as indicator of injury and toxicity (Farah *et al.,* 2013). Hypertrophy of organs resulting from oedema from inflammation indicates toxicity and damaged to organs (Ping *et al*., 2013). Free radicals generated during doxorubicin metabolism cause destruction of hepatic, cardiac and kidney cells and tissues. The decrease in weights of liver, following the administration of the extract and fractions is as a result of protective effect of the extract against the effect of free radicals generated by doxorubicin. This could have resulted from antioxidative burst and antioxidant activities of the root extract and fractions of *H. africana* as previously reported (Okokon *et al.*, 2013a;2022; Umoh *et al.,* 2021). These activities may have contributed to the observed protective effects in this study.

The administration of doxorubicin on alternate days for 14 days to rats was found to cause a significant ($p<0.001$) elevation in the levels of AST, ALT, ALP, total and combined bilirubin and decreases in total protein and albumin levels when compared to control. These elevations were considered to be manifestations of serious damage to the liver. Concomitant administration of root extract and fractions of *Hippocratea africana* (200 -600 mg/kg) with doxorubicin (1.66 mg/kg, i.p) for 14 days caused observable significant ($p<0.001$) decreases of these enzymes

levels and that of total and combined bilirubin in the extract-treated groups when compared with the DOX only group. Assessment of liver function can be made by estimating the activities of serum ALT, AST, ALP, bilirubin (total and direct), total cholesterol, total protein and albumin which are originally present in the cytoplasm (Manokaran *et al.,* 2008). When there is liver damage, these enzymes and molecules leak into the blood stream, which serves as an indicator for the liver damage (Nkosi *et al.,* 2005). The reduction of the levels of these enzymes and molecules by the root extract and fractions in this study is as a result of their free radical scavenging potentials, which protected the liver against oxidative stress by free radicals generated by doxorubicin. The effect may have resulted from the antioxidant activities of its phytoconstituents. This result agrees with earlier study by Okokon *et al.,* (2013a) in which significant protection of the liver against paracetamol-induced liver injury by the root extract of this plant was reported.

The findings of this study showed that administration of doxorubicin on alternate days for 14 days to rats caused significant decreases ($p<0.05$) in levels of enzymatic and non enzymatic endogenous antioxidants (GSH,SOD, CAT, GPX and GSH) when compared to control. Elevated level of MDA was also observed. Lipid peroxidation is a marker of oxidative stress and elevations in the amount of malondialdehyde (MDA), a lipid peroxidation product, have been reported following DOX treatment (Rashid *et al.,* 2013, Rehman *et al.,* 2014, Khames *et al.,* 2019). This trend was observed in this study. Concomitant administration of root extract and fractions *H. africana* (200 - 600 mg/kg) with doxorubicin caused significant ($p<0.05$-0.001) non dose- dependent

elevation in the levels of the antioxidant enzymes (SOD, CAT, GPx) when compared to control. Similarly, GSH level was significantly ($p<0.001$) elevated following treatment with the extract when compared to control. Similarly, there were significant ($p<0.05$-0.01) reductions in the level of MDA of the extract-treated rats. It has been documented that DOX inhibits the activities of endogenous enzymatic and nonenzymatic antioxidants. So, an imbalance between ROS generation and neutralization leads to oxidative stress and injury to the liver (Abushouk *et al.,* 2017; Abdel-Daim *et al.,* 2017; Aboushouk *et al.,* 2019). The reduction of MDA level by the extract and fractions demonstrates a reduction in lipid peroxidation and free radicals generation which might have been scavenged by the phytoconstituents present in this extract and fractions, hence the protective effect on the liver.

Doxorubicin was found in this study to cause necrosis of liver cells leading to damages and obstruction of liver functions. This effect was however counteracted by the leaf extract. DOX mediated hepatotoxicity are seen as focal damage in hepatocytes, vascular damage and steatosis (Pedrycz *et al.,* 2004). DOX in the form of DOX semiquinone, which generates free radicals, has been suggested to play a major role in its hepatotoxic action (Bachur *et al.,* 1979). The antioxidant potentials of the phytoconstituents in the root extract may have contributed to the hepatoprotective effect observed in this study.

Conclusion

The findings of this study showed that the root extract and fractions of *Hippocratea africana* had the potentials to counteract the injurious effect of doxorubicin on the liver. This activity

can be attributed to the antioxidant and antioxidative stress activities of its phytochemical constituents. Thus, the leaf can be used to alleviate and/or prevent doxorubicin-induced hepatotoxicity.

Acknowledgement

The authors are grateful to staff of Animal house, Department of Pharmacology and Toxicology, University of Uyo, Uyo for their technical assistance

Conflicts of interest

The authors declare no conflict of interest

References

Abdel-Daim MM, Kilany OE, Khalifa HA, Ahmed AAM. (2017). Allicin ameliorates doxorubicin-induced cardiotoxicity in rats via suppression of oxidative stress, inflammation and apoptosis. Cancer Chemotherapy and Pharmacology, 80(4): 745–753.

Abushouk AI, Salem AMA, Saad A. (2019). Mesenchymal stem cell therapy for doxorubicin-induced cardiomyopathy: potential mechanisms, governing factors, and implications of the heart stem cell debate. Frontiers in Pharmacology, 10: 635.

Abushouk AI, Ismail A, Salem AMA, Afifi AM, Abdel-Daim MM. (2017). Cardioprotective mechanisms of phytochemicals against doxorubicin-induced cardiotoxicity. Biomedicine & Pharmacotherapy, 90: 935–946.

Ajibesin K K, Ekpo BA, Bala D N, Essien E E, Adesanya SA.(2008). Ethnobotanical survey of Akwa Ibom State of Nigeria. J Ethnopharm 115: 387 – 408..

Bachur NR, Gordon SL, Gee MV, Kon H. (1979). NADPH-cytochrome P450 reductase activation of quinone anticancer agents to free radicals. Proceedings of the National Academy of Sciences USA. 76: 954-957.

Drury RA, Wallington EA. (1980) Carleton's Histological Techniques. 5th Edition, Oxford University Press, New York, 195.

Ellman GL. (1959). Tissue Sulfhydryl Groups. Archives of Biochemistry and Biophysics, 82: 70-74.

Esterbauer H, Cheeseman KH. (1990). Determination of aldehydic lipid peroxidation products: malonaldehyde and 4-hydroxynonenal. Methods in Enzymology. 186: 407–421.

Farah AO, Nooraain H, Noriham A, Azizah AH, Nurul HR. (2013). Acute and oral subacute toxicity study of ethanolic extract of *Cosmos caudatus*

leaf in Sprague Dawley Rats. International Journal of Biosciences, Biochemistry and Bioinformatics. 3(4): 301-305.

Hutchinson J, Dalziel JM. 1973. Flora of West Tropical Africa. 2nd edition. Crown Agents for Overseas Government and Administration, Vol.1, Part 2, p.638.

Khames A, Khalaf MM, Gad AM, Abd El-Raouf, OM, Kandeil MA. (2019). Nicorandil combats doxorubicin-induced nephrotoxicity via amendment of TLR4/P38 MAPK/NFj-B signaling pathway. Chem. Biol. Interact., 311, 108777.

Lawrence RA, Burk RF. (1976). Glutathione peroxidase activity in selenium- deficient rat liver. Biochemistry Biophysics Research Communications 71: 952-958.

Manokaran S, Jaswanth A, Sengottuvelu S, Nandhakumar J, Duraisamy R, Karthikeyan D, Mallegaswari R. (2008). Hepatoprotective activity of *Aerva lanata* Linn. against paracetamol induced hepatotoxicity in rats. Research Journal of Pharmacy and Technology. 1: 398–400.

Marklund S, Marklund G. (1974). Involvement of superoxide anion radical in the autooxidation of pyrogallol and a convenient assay for superoxide dismutase. European Journal of Biochemistry. 47: 469 - 474.

Nkosi CZ, Opoku AR, Terblanche SE. (2005). Effect of pumpkin seed (*Cucurbita pepo*) protein isolate on the activity levels of certain plasma enzymes in CCl_4-induced liver injury in low-protein fed rats. Phytotherapy Research. 19(4): 341-345

Okokon J E, Ita BN, Udokpoh A.E. (2006). The *in vivo* antimalarial activities of *Uvaria chamae* and *Hippocratea africana*. Annals Trop Med Parasitol 100:585-590.

Okokon JE, Akpan HD, Ekaidem I, Umoh EE. (2011). Antiulcer and antidiarrheal activity of *Hippocratea africana.* Pak J Pharm Sci 24:201- 205.

Okokon JE, Antia BS, Umoh EE, Etim EI. (2010). Antidiabetic and hypolipidaemic activities of *Hippocratea africana*. Int J Drug Dev Res 2: 501 -506.

Okokon JE, Antia BS, Umoh EE. (2008). Analgesic and antinflammatory effects of ethanolic root extract of *Hippocratea africana.* Int J Pharmacol l4 (1):51-55.

Okokon JE, Chinyere CP, Bassey AL, Udobang JA. (2021). *In vivo* alpha amylase and alpha glucosidase activities of ethanol root extract and fractions of *Hippocratea africana*. South Asian J Parasitol 5(4): 42-48.

Okokon JE, Chinyere PC, Amaechi P, Bassey AL, Thomas PS (2022). Antioxidant, antidiabetic and hypolipidemic activities of ethanol root extract and fractions of *Hippocratea africana*. Tropical Journal of Natural Product Research. 6(3):446-453.

Okokon JE, Dar A, Choudhary MI. (2013b). Immunomodulatory, cytotoxic

and antileishmanial activities of *Hippocratea africana.* J Nat Pharmaceut 4 (2):81 – 85.

Okokon JE, Davies K, Okokon PJ, Antia BS. (2014). Depressant, anticonvulsant and antibacterial activities of *Hippocratea africana*. Int J Phytother 4 (3):144 – 153.

Okokon JE, Nwafor PA, Charles U, Dar A, Choudhary MI. (2013a). The antioxidative burst and hepatoprotective effects of ethanolic root extract of *Hippocratea africana* against paracetamol-induced liver injury. Pharm Biol 51 (7):872 - 880.

Okokon JE, Okokon PJ, Sahal D. (2017). *In vitro* antiplasmodial activity of some medicinal plants from Nigeria. Int J Herbal Med 5 (5):102-109.

Olorundare OE, Adeneye AA, Akinsola AO, Sanni DA, Koketsu M, Mukhtar H. (2020). *Clerodendrum volubile* Ethanol Leaf Extract: A Potential Antidote to Doxorubicin-Induced Cardiotoxicity in Rats. Journal of Toxicology, Volume 2020, Article ID 8859716, 17 pages.

Olorundare OE, Adeneye AA, Akinsola AO, Sanni DA, Koketsu M, Mukhtar H. (2020). *Clerodendrum volubile* ethanol leaf extract: a potential antidote to doxorubicin-induced cardiotoxicity in rats. Journal of Toxicology, Volume 2020, Article ID 8859716, 17 pages.

Pedrycz A, Wieczorski M, Czerny K. (2004) The influence of a single dose of adriamycin on the pregnant rat female liver- histological and histochemical evaluation. Ann Univ Mariae Curie Sklodowska. 59:319 -323.

Ping KY, Darah I, Chen Y, Sreeramanan S and Sasidharan S. (2013). Acute and subchronic toxicity study of *Euphorbia hirta* L. methanol extract in rats. Biomedical Research International. 2: 1-14.

Rashid S, Ali N, Nafees S, Ahmad ST, Arjumand W, Hasan SK, Sultana S. (2013). Alleviation of doxorubicin-induced nephrotoxicity and hepatotoxicity by chrysin in Wistar rats. Toxicology Mechanisms and Methods, 23: 337–345.

Raškovi A, Stilinovi N, Kolarovi J, Vasovi V, Vukmirovi S.(2011). The protective effects of silymarin against doxorubicin-induced cardiotoxicity and hepatotoxicity in rats Molecules 16: 8601-8613

Rehman MU, Tahir M, Khan AQ, Khan R, Oday OH, Lateef A, Hassan SK, Rashid S, Ali N, Zeeshan M, Sultana S. (2014). D-limonene suppresses doxorubicin-induced oxidative stress and inflammation via repression of COX- 2, iNOS, and NFjB in kidneys of Wistar rats. Exp. Biol. Med. (Maywood) 239:465–476.

Sinha AK.(1972). Colorimetric assay of catalase. Analytical Biochemistry, 47: 389 - 94.

Umoh UF, Thomas PS, Essien EE, Okokon JE, De Leo M, Ajibesin KK, Flamini G, Eseyin OA. (2021). Isolation and characterization of bioactive

xanthones from *Hippocratea africana* (Willd.)Loes.ex Engl. (Celastraceae). Journal of Ethnopharmacol. 280:114031.