Extracts of *Gnetumafricanum*(*Gnetacae*) Ameliorated Liver Injuries of Cyclophosphamide Immunosuppressed Rats

Ngozi U. Madubogwu[1*], Prince C.Unekwe[2], Earnest O.Erhirhie[1], Festus B.C. Okoye[3]

[1]Department of Pharmacology and Toxicology,Faculty of Pharmaceutical Sciences

Chukwuemeka Odumegwu Ojukwu University, Anambra State, Nigeria

[2]Department of Pharmacology and Therapeutics, Faculty of Basic Clinical Sciences, Nnamdi Azikiwe University Awka, Anambra State,Nigeria.

[1]Department of Pharmacology and Toxicology,Faculty of Pharmaceutical Sciences

Chukwuemeka Odumegwu Ojukwu University, Anambra State, Nigeria

[3]Department of Pharmaceutical and Medicinal Chemistry, Faculty of Pharmaceutical Sciences, Nnamdi Azikiwe UniversityAwka, Anambra State, Nigeria.

Submitted 10/02/2022; Accepted 14/02/2022; published online 28/02/2022

https://doi.org/10.54117/jcbr.v2i1.2

Corresponding Author: Ngozi U. Madubogwu**;** mngoziukamaka@yahoo.com

ABSTRACT

Gnetum africanum(*Gnatacae*) is a ceremonial delicacy in many parts of Eastern Nigeria and the leaves are either eaten raw or are finely shredded and added to soup.The effect of cyclophosphamide (CP) administration on the liver biomarkers of albino rats and the possible protective role of *G.africanum* extract was studied.

Thirty rats were randomly divided into six groups of five rats each. Groups I-V were injected intraperitoneally with 70 mg/kg of CP on the first day while group VI was not injected with cyclophosphamide. Group I received 10 mL/kg of distilled water orally. Groups II, III and IV received daily dose of 50, 100and 200 mg/kg of extract respectively and group V received levamisole (2.5 mg/kg) for 14 days. The rats were sacrificed 24h after thelast dose and blood samples collected through cardiac puncture into non-heparinized tubes, allowed to clot for 30 min and sera obtained was used for determination ofaspartate amino transaminase (AST), alanine amino transaminase (ALT) and alkaline phosphatase (ALP). Histopathology of rat liver was also carried out. Treatment with *G. africanum* ethanol extract produced significant ($P<0.05$) decrease in the values of ALT and AST while there were no significant changes ($P>0.05$) in ALP in Cyclophosphamide induced group. Histopathology examination of liver sections of untreated control group showed hypertrophied central vein with moderate purulent exudates accumulation while those treated with the extracts ameliorated the hepatic damage caused by CP.

The present work revealed that *G.africanum* ethanol extract exerts liver protective effect in albino rats exposed to CP and may offer useful application as supplemental agent in the management of hepatic injuries arising from chemotherapy.
Keywords: *G. africanum*, hepatic injuries Cyclophosphamide, Levamisole, Liver biomarkers.

Introduction:

Cyclophosphamide (CP) is a cytotoxic alkylating agent used for the treatment of neoplastic diseases such as solid tumors and lymphomas as well as an immunosuppressive agent for organ transplantation, multiple sclerosis, systemic lupus erythematosus and other benign tumors(Lawson et al.,2008). Its ability to damage normal tissue as well as cancerous tissues which normally results in multiple organ toxicity has limited its clinical use (Fraiser et al.,1991). One of the major side effects of CP is hepatotoxicity as it is metabolized by hepatic microsomal cytochrome p450 mixed function oxidase system resulting in the production of two active metabolite phosphoramide mustard and acrolein(King and Perry,2001). The immunosuppressive and antineoplastic effect of CP is attributed to phosphoramide while its toxic effect is associated with acrolein. It has also been found that the hepatotoxic effect of CP is also associated with oxidative stress(Oyagbemi et al.,2016;Singh et al.,2018).The exposure of the liver to CP usually result to injury which can lead to deterioration of its functions and may result in organ failure(wang et al.,2019).

The use of orthodox medicines for treatment of liver diseases often produced limited results withseveral side effects. Therefore, the use of complementary and alternative herbal medicine is gaining research interest as alternative hepatoprotective agents capable of ameliorating or reversing liver injury with little or no side effects (Zhang et al.,2012).Levamisole, a synthetic imidazothiazole derivative is an anti nematodal drug with a broad range of activity against a large number of hosts. The drug has an immunostimulating effect. It also, stimulate formation of antibodies to various antigens, by stimulating T-cell activation and proliferation, potentiate monocyte and macrophage functions including phagocytosis and chemotaxis and increase neutrophil adhesion(Mariam et al., 2015).

Gnetum africanum (*family,Gnetacae*),locally called ‘afang’ by (Efik) and ‘okazi’ by Igbos in Nigeria is a perennial herbthat grows approximately 10 metres long, with thick papery-like leaves growing in groups of three. *Gnetum africanum* is referred to as a form of wild spinach in English (Ali *et al.,* 2011). It is a ceremonial delicacy in many parts of Eastern Nigeria up to the southern part of Nigeria; its use has spread to towns and cities like Abuja, Lagos, Ibadan and Markudi (Iloh et al.,2009). It is also one of the vegetables in great demand by Nigerians in Diaspora and it is very expensive. The leaves are either eaten raw or are finely shredded and added to soup and stews (Iloh *et al.,* 2009*)*. Phytochemical studies on the leaves showed the presence terpenoids, saponins, tannins, steroids, flavonoids, alkaloids, cardiac glucosides and phenols (Ogbonnaya et al.,2013; Ezekwe et al.,2020). Studies have revealed that GA possesses desirable health benefit such as anti-inflammatory (Burkill,1994), antimicrobial and antifungal(Egeonu et al.,2013;Ilodibia et al.,2015, Eneh et al.,2017), anti-sickling properties (Ngboluaet al.,2016) and immunostimulatory properties (Madubogwu et al.,2021).Several studies have also reported its antioxidant properties(Ogbonnaya et al.,2013; Kongkachuichai et al.,2015, Ezekwe et al.,2020). The study therefore aimed at examining the protective effect of ethanol extract of *G. africanum* in a cyclophosphamide induced hepatotoxicity.

Materials and Methods

Plant material

The leaves of *G.africanum*were obtained from a local market in AforNnobi, Idemili South Local Government Area, Anambra State, Nigeria in March 2020. They were identified by Mrs Onwunyili Amaka of the

Department of Pharmacognosy and Traditional Medicine, NnamdiAzikiwe University, Agulu Campus and a voucher specimen PCG/474/A/066 was deposited in the herbarium of the department.

Solvents and reagents

Drugs used were cyclophosphamide(ZuviuslifesciencesPvtLtd,India), and levamisole (Medrel Pharm India).Diagnostic kits used for the estimation of biochemical assays is Hipro(Biotechnology Corp, Guangzhou). Anesthetic ether (Guangdong Sci.-tech Co.Ltd, Shantou China), ethanol (80%) (Guangdong Sci.-tech Co.Ltd, Shantou China) were also used. All other chemicals and reagents used were of analytical grade.

Experimental animals

Equal number of male and female adult Wistar rats weighing between 180-200 were procured from the Department of Veterinary Parasitology and Entomology, Faculty of Veterinary Medicine, University of Nigeria, Nsukka. Female animals were nulliparous, and male animals were separated from female animals in their various cages.The animals were fed with normal feeds (Guinea feed Nigeria Ltd) and had unrestricted access to clean drinking water. Ethical approval wasobtained from the ethical committee of ChukwuemekaOdumegwuOjukwuUniversity Teaching Hospital, Awka with approval no, COOUTH/CMAC/ETH.C/VOL.1/FN:04/0064 before commencement of the study. The guide for the care and use of laboratory animal procedures was followed in the study.

Preparation and extraction of plant materials

Fresh leaves of *G. africanum*were air -dried under shade for five (5) days. The dried leaves were pulverized into a fine powder using a grinding machine. Then 1 kg of the powdered leaves of *G. africanum*was extracted using cold maceration in 5 L of ethanol for 72 h with intermittent shaking. The supernatant was decanted after 24 h, and fresh ethanol was used to make up the original mark and was left for another 48 h after which the mixture was sieved with a muslin cloth. It was further filtered three times with No1 Whatman filter paper. The filtrate was concentrated using a rotary evaporator at40ºC as well as water bath at 45ºC. The weight of the concentrated extract was obtained using weighing balance and it was stored in a closed container at 4ºCin a refrigerator for further use.

Experimental design

The method of Birhanu et al.,(2018) was adapted. A total of 30 adult rats weighing (180-200g) were grouped into six groups of five rats each. All the animals in groups one to five received single intraperitoneal administration of 70 mg/kg cyclophosphamide. The group six animals were the normal control.

Group I received 10 mL/kg distilled water p.o

Group II received 50 mg/kg of the crude extract p.o

Group III received 100 mg/kg of the crude extract p.o

Group I V received 200 mg/kg of the crude extract p.o

Group V received levamisole, 2.5 mg/kg

GroupVI normal control

The animals were treated for fourteen days after which they were anaesthetized with ether and blood samples were collected from the animals through cardiac puncture into centrifugal tubes and allowed to clot for 30 min. The clotted blood samples were centrifuged to separate the cells from the serum. Sera were then aspirated into labeled vials and stored in the freezer until

ready to use while the liver was harvested for histological examinations.

Enzymes assays

Serum levels of aspartate aminotransferase (AST), alanine aminotransferase (ALT), alkaline phosphatase (ALP), were determined by standard methods described by Reitman and frankel, (1957) and King Amstrong (1934) using commercial reagent kits.

Histopathological Examination

This was carried out on the excised organs according to the method described by Lamb. (1981). Organ pieces (3-5µm thick) was fixed in 10% solution of buffered formalin for 24 h and washed in running water for 24 h. Samples were dehydrated in ascending grades of ethanol in an autotechicon. The tissues were thereafter cleared in chloroform overnight to remove absolute alcohol. The cleared samples were infiltrated and embedded by passing them through three cups containing molten paraffin at 50ºC and then a cubical block of paraffin made by L moulds. The blocks were later trimmed by microtome and sectioned at 5-6 microns. The sections were deparaffinized in xylene, taken to water and were subsequently stained with hematoxylin and eosin (H &E) for light microscopy.

Statistical analysis

Data generated were presented as mean ± SEM and subjected to one-way analysis of variance (ANOVA) using the program graph pad prism version 5 followed by a post-hoc dunnette'stest.The p values <0.05 and $p<0.01$ were taken as statistically significant.

RESULTS AND DISCUSSION

Effect of ethanol leaf extracts of *G. africanum* on liver enzymes.

Cyclophosphamide (70 mg/kg body weight) induced elevated levels of serum AST, ALT and ALP in the untreated control group. Elevated serum enzymes are indicative of cellular leakage and loss of functional integrity of the cell membrane in liver (Amresh et al., 2007; Drotman& Lawhorn,1978). Hence, significant rise in the serum enzyme levels could be taken as an index of liver damage (Lim et al.,2000). Ethanol leaf extract of *G. africanum*and levamisole ameliorated the elevated serum enzymes. The extracts and levamisole showed significant alteration in the values of ALT and AST ($p<0.01$) when compared to the negative control while there was no significant alteration ($p>0.05$) in the value of ALP when compared to control group.

The above investigation was consistent with the results of the study done by Udeh*et al.* (2018) and Udoh*et al*. (2011) as both studies recorded significant decrease ($P<0.05$) in the values of AST, ALT and ALP but contrasted with the study done by Iweala*et al.* (2009) and Oguwike*et al.* (2018) in which they found no significant alterations ($P>0.05$) in the values of AST, ALT and ALP in the treated rats when compared to the control.

Treatment with 80% ethanol extract of the leaves of *G.africanum* attenuated the increased activities of these enzymes caused by cyclophosphamide, which suggest recovery towards normalization, and the possibility that*G. africanum* extract causes parenchymal cell regeneration in liver, thus protecting membrane fragility (Table 1). Liver injury of various etiologies has been found to be reduced by levamisole which act as a free radical scavenger (Farghali& Masek, 1998).

Table 1: EFFECT OF CRUDE ETHANOL EXTRACT OF *G. africanum* LEAVES ON LIVER MARKERS

Group	ALT	ASP	ALP
CP. Induced control	45.00 ±2.52	68.67±2.60	52±2.31
50mg/kg extract	36.33±0.88*	52±0.58**	48.33±0.88
100 mg/kg extract	33.33±1.67**	49±0.58**	50.67±1.45
200 mg/kg extract	25.67±1.20**	42.33±2.01**	50.33±4.91
Levamisole, 2.5 mg/kg	29.00 ±0.58**	50±1.16**	50.33±1.67
Normal control	26.33±1.20**	44.33±1.86**	51.00±4.36

Results are presented as mean ± standard error of mean, n = 5. nsP>0.05; Not statistically significantly different from control group. *P<0.05; Statistically significantly different from control group. **P<0.01; Statistically significantly different from control group.

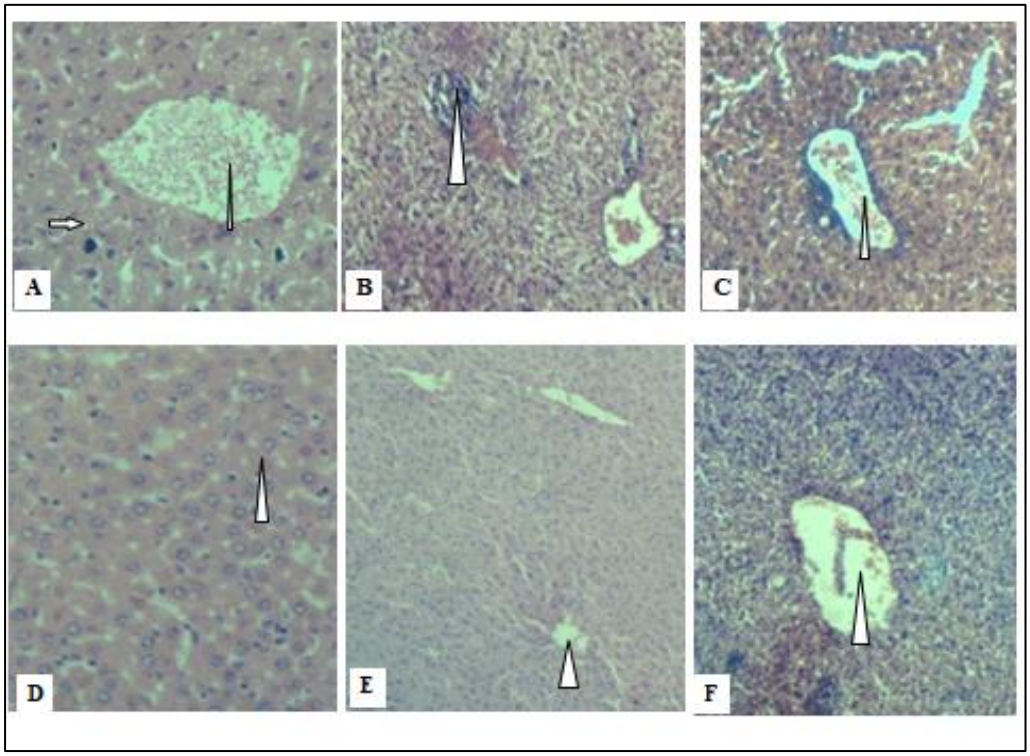

Fig. 1: Histopathology results.

Plate A: Tissue Histology photomicrograph of the liver of cyclophosphamide induced rat Treated with 10 ml/kg of distilled water. A section of liver tissue shows hypertrophied central vein with moderate purulent exudates accumulation within the vessel (arrow head) and some unremarkable hyperchromatic hepatocytes (arrow) (H&E, X400).

Plate B: Tissue histology photomicrograph of the liver of cyclophosphamide induced rat treated with 50 mg/kg of the extract. A section of liver tissue shows multiple areas of inflammatory exudation with mild infiltration of inflammatory cells (X400, H&E).
Plat C: Tissue histology photomicrograph of the liver of cyclophosphamide induced rat treated with 100 mg/kg of the extract. A section of liver tissue shows hypertrophied central vein with signs of haemorrhage within the vessels (H&E, X400).
Plate D: Tissue Photomicrograph of the liver of cyclophosphamide induced rat treated with 200 mg/kg of the extract. A section of liver tissue shows normal morphology of hepatocytes and sinusoids (X400, H&E).
Plate E: Tissue histology photomicrograph of liver cyclophosphamide induced rat treated with 2.5 mg/kg levamisole. A section of liver tissue shows normal morphology of hepatocytes and central vein (X400, H&E)
Plate F: Tissue Histology Photomicrograph of Liver of Normal Rat. A section of liver tissue shows normal morphology with hepatocytes and central vein intact (X400, H&E).

Effect of ethanol leaf extracts of *G. africanum* on histopathology of the liver of cyclophosphamide immunosuppressed rats.

The photomicrographs of the liver section of the normal rats showed that the liver tissue have normal morphology with hepatocytes and central vein intact (plate F). A section of liver tissue of the rat induced with cyclophosphamide showed hypertrophied central vein with moderate purulent exudates accumulation within the vessel and some unremarkable hyperchromatic hepatocytes (plate A). A photomicrograph of the liver section of cyclophosphamide rats treated with 50 mg/kg of the ethanol leaf extract of *G.africanum* showed multiple areas of inflammatory exudation with mild infiltrationof inflammatory cells (plate B). Liver section of cyclophosphamide induced group treated with 100 mg/kg of the extract showed hypertrophied central vein with signs of haemorrhage within the vessel (plate C). This might be due to side effect of cyclophosphamide which includes bleeding. A photomicrograph of the liver section treated with 200 mg/kg of the extract showed normal morphology of the hepatocytes and sinusoids (plate D).A photomicrograph of the liver sections of the group treated with 2.5 mg/kg levamisole also showed normal morphology of the hepatocytes and sinusoids (plate E).

Liver is known to be involved in metabolic degradation of both natural and synthetic chemicals, during which process hepatotoxic metabolites might be generated leading to liver injury and this was seen in the group treated with cyclophosphamide only. There is an increasing evidence for the hepatoprotective role of phytochemical substances from vegetables, fruits and some herbs (Weichiu*et al*., 2013; Ajah et al., 2021). The above result showed that the ethanol leaf extract of *G.africanum* had hepatoprotective effect. The effect of the extract was dose dependent. The study was in consonant with the work done by Iweala*et al*. (2009). The hepatoprotective effect of *G.africanum* observed in this study could be attributed to its ability to scavenge, mop-up, and neutralized cyclophosphamide generated free radicals. *G. africanum* is reported to be rich in saponins, terpenoids, and flavonoids which made it a scavenger of free radicals (Ilodibia et al.,2015;Ezekwe et al.,2020; Madubogwu et al.,2021). Flavonoids were most commonly known for their antioxidant activities.They acts as detoxifiers with the ability to modify a cells reactions to carcinogens, viruses and allergens. Balch and Balch. (2000) reported that flavonoids also possess antimicrobial, anticancer, anti-inflammatory and anti-allergic activities. Saponins have been reported to exhibit a wide range of

pharmacological and medicinal activities. Sood *et al.*(2012) reported that they enhanced natural resistance and the recuperative powers of the body and were also good hemagglutin.

CONCLUSION:

From the present study, cyclophosphamide administration resulted in elevation of liver enzymes which was reversed by treatment with ethanol extract of *G. africanum*. Histopathological examinations also confirmed the protective effects of *G. africanum* against CP-induced liver damages. Because *G.africanum* has been shown to possess different pharmacological activities, it could be a potential candidate for a safe supplemental agent against the side effects of chemotherapy.

CONFLICT OF INTEREST

The authors declare no conflicts of interest

REFERENCES

Ali F, Assanta MA, Robert C (2011). *Gnetum africanum:* A Wild Food Plant from the African Forest with Many Nutritional and Medicinal Purposes. J. Med. Food 14 (11), 1289-1297

AmreshG, RaoCV, Singh PN(2007): Evaluation of *Cissampelospareira* on gastric cancer and enzymes associated with carcinogen metabolism. Pharm Biol 45: 595–603.

Ajah KU, Asomugha ON, Ifedigbo CP, Umeh KC, Obidiegwu OC, Okoye NN, Ajaghaku AU, Omoriri MA, Okoye FBC (2021). Evaluation of the antioxidant potentials of extract and fractions of *Vitex doniana* fruit and identification of the bioactive metabolites using HPLC-DAD-MS analysis. GSC Biological and Pharmaceutical Sciences. 17(1): 160–175

Balch JF, Balch PA (2000). Prescription for Nutritional Healing.New York: Avery, Penguin Putnam Inc, Birhanu BT, Kim J, Park S(2018). An in vivo immunomodulatory and anti- inflammatory study of fermented *Dendropanaxmorbifera*Leveille leaf extract. BMC Complement. Med. Ther.18(222),2018.

Burkill HM (1994). The Useful Plants of West Tropical Africa: Families M-R.2nd edition, Royal Botanic Gardens Michigan DrotmanRB, LawhornGT(1978): Serum enzymes are indicators of chemical induced liver damage. Drug ChemToxicol 1,163–171

Egeonu SU, Enyi-Idoh KH, Ikpeme EM, Iwu GC, Mandor B, Ofor UC (2013).Anti-bacteria activity of *Gnetumafricanum*and*Heinsiagrinita* on Diarrhoeagenic bacteria isolate from Childrenin Calabar South LGA,Cross River State. Trans. J. Sci.Technol 3(3),1857-80.

Eneh FU, Onwubiko CE, Ugochukwu GC (2017).Phytochemical and antimicrobial screening of *Gnetumafricanum*leaf extracts.Intern. J. Herb Med 5(3):105-107.

Ezekwe A, Ugwuezumba P, Nwankpa P, Egwurugwu J, Ekweogu C, Emengaha F, Akukwu D. Qualitative Phytochemical Screening, GCMS Studies and In-Vitro Anti-Oxidative Properties of Aqueous Leaf Extract of Gnetumafricanum. JDDT [Internet]. 15Jan.2020 [cited 31Jan.2022];10(1):11-7. Available from: http://jddtonline.info/index.php/jddt/article/view/3813

Farghali H, Masek K(1998). Immunopharmacologic agent in the amelioration of hepatic injuries. Int J Immunopharmacol 20(4-5),125-39.

Fraiser LH, KanekelS,Kehrer JP(1991). Cyclophosphamide toxicity. Characterizing and avoiding the problem. Drugs 42:781-795.

Ilodibia CV, Ugwu RU, Nwokolo OL, ChukwumaMU,Akachukwu EE(2015).Phytochemical

Screening, Antifungal and Antibacterial Activity of Aqueous and Ethanolic Leaf and Stem

Extracts of *Gnetumafricanum*Welw.*Research* J. Med. Plant 9 (6), 275-283

Iloh AC, Isu NR, KutaDD(2009). Invitro Callus Initiation of a Threatened Nigerian Leafy

Vegetables, *Gnetumafricanum*(WILW). Int.J. Biodivers. Conserv. 1(4), 081-086.

Iweala EE, Uhegbu FO, ObidoaO(2009). Biochemical and histological changes associated with long term consumption of *Gnetumafricanum*Welw. Leaves in Rats. *Asian Journal of Biochemistry 4: 125-132.*

King EJ, Armstrong AR(1934). A convenient method for determining serum and bile phosphatase activity. *Journal of Canadian Medical Association 31(4):376–381.*

King PD, Perry MC (2001). Hepatotoxicity of chemotherapy. Oncologist 6:162-76.

Kongkachuichai R, Charoensiri R, Yakoh K, Kringkasemsee A, Insung P (2015). Nutrients value and antioxidant content of indigenous vegetables from Southern Thailand. Food Chem. 173, 838–846

LambGM (1981).Mannual of Verterinary techniques in Kenya.CIBA-GEGY, Kenya pp100.

Lawson M, Vasilaras A, De Vries A, Mactaggart P, Nicol D(2008). Urological implications of cyclophosphamide and ifosfamide. Scand J UrolNephrol42,309-17.

Lim HK, Kim HS, Choi HS, OhS Jang, CG, Choi J, KimSH, Chang MJ(2000): Effects of acetylbergenin against d-galactosamine induced hepatotoxicity in rats. Pharmacol Res 5, 471–474

MadubogwuNU,UnekwePC,ErnirhieEO,ChukwurahIB,AjaghakuDL,Okoye FBC(2021). Evaluation of the immunomodulatory activity of Gnetumafricanum(Gnatacae) leaf extracts.Trop J Nat Prod Res 5(11),2034-2050.

Mariam GE, Hassanenem MM, Ibrahim MF, Nermeen MS (2015). Evaluation of protective and therapeutic role of *Moringa oleifera*leaf extract on CCL4 induced genotoxicity, hemotoxicity and hepatotoxicity in rats Int. J. Pharm Tech Res 7: 392-415.

Ngbolua K, Mpiana PT, Akoundze JB, Mwanza FB, Tshibangu DS, Ashande MC, Liesse JL, Kikuni T(2016). Anti-sickling and Bacterial Inhibitory Effects of Two MedicinalFoods from

Congo River Basin: *Gnetumafricanum*Welw. (Gnetaceae) and *Grewiacoriacea*Mast. (Malvaceae).Curr. Tradit Med.2,34-41.

Ogbonnaya EC, Eleazu KC (2013). Health Promoting Compounds and Invitro Antioxidant activity of raw and Decoctions of*Gnetumafricanum.* Asian Pac.J. Trop. Dis.3(6),472-479.

Oguwike FN, Ifedi IC, Dim CN, Igwedibia CP, Ogu EC, Elochukwu VI, Alajekwu JC, Offor

CC(2018).Biochemical and Haemopoietic Effects of Aqueous Extract of *Gnetumafricanum*

(Ukazi) on Male and Female Albino WistarRats**.***Greener* J. Med.Sci. 8(4), 061-065.

Oyagbemi AA, Omobowaje RO, Saba AB(2016).Cyclophoshamide induced Hepatotoxicity in Wistar Rats: The Modulatory role of Gallic Acid as a Hepatoprotective and Chemopreventive Phytochemical. Int JPrev Med 7,51

Reitman S, Frankel S (1957). A colorimetric method for the determination of serum glutamate oxaloacetate and pyruvate transaminase.Am. J. Clin.Pathol 28,56-63.

Singh C, Prakash C, Tiwari K, Mishra SK, Kumar V (2018).Premna integrifolia ameliorates Cyclophosphamide-induced hepatotoxicity by modulation of oxidative stress and apoptosis. Biomed. Pharmacother. 107, 634-643.

Udeh NE, Anaga A, Asuzu IU (2018). Effects of Gnetumafricanum (Welw) methanol leaf extract on weight and haematological profile of wistar rats following chronic oral administration. Sokoto J.Vet.Sci.16(3): 49-54.

Udoh FV, Ekanem A, Ebong PE (2011).Effect of alkaloids extract of gnetumafricanum on serum enzymes levels in albino rats. J. Appl. Pharm. Sci.1(9),29-32

Wang S, Luan JJ, Lv XW (2019) Inhibition of endoplasmic reticulum stress attenuated ethanol-induced exosomal miR-122 and acute liver injury in mice. Alcohol 54, 465–471

WeiChiu Y, JenLo H, YuHuang, YuChao P, Hwang J, YunHuang P(2013). The antioxidant and cytoprotective activity of *Ocimumgratissimum*extracts against hydrogen peroxide-induced toxicity in human HepG2 cells.J. Food Drug Anal. 21(3),253-226.

Sood A, Kaur P, Gupta R (2012). Phytochemical screening and antimicrobial assay of various seeds extract of cucurbitaceae family. Int.J. Appl. Biol Pharm.3(3),401-409.

Zhang H, Yu C-H, Jiang Y-P, Peng C, He K, Tang J-Y, Xin H-L (2012) Protective effects of polydatin from *Polygonumcuspidatum* against carbon tetrachloride-induced liver injury in mice. PLoS One 7(9):e46574