# Endometrial metaplasia in a grand multiparous Nigerian woman; A case report with a review of literature

Uchendu Jude Obiora[*1], Uchendu Adaeze Phina[2], Sokoh Akpo Coup[3], Okhionkpamwonyi Osamudia[4], Oghounu Uwhomano[5]

[1]Department of Morbid Anatomy and Histopathology, Delta State University, Abraka, Delta State, Nigeria.
[2]Department of Pharmacology and Toxicology, Faculty of Pharmacy, University of Benin, Benin City, Edo State, Nigeria.
[3]Department of Pathology, Delta State University Teaching Hospital, Oghara, Delta State, Nigeria.
[4]Department of Obstetrics and Gynecology, Delta State University Teaching Hospital, Oghara, Delta State, Nigeria.
[5]Best-Link Hospital, Ugheli, Delta State, Nigeria.

*Submitted: 6th Oct., 2022; Accepted: 10th Oct., 2022; Published: 31st Dec., 2022*
*DOI: https://doi.org/10.54117/jcbr.v2i6.6*
*[*]Corresponding author: Uchendu Jude Obiora; **ojlinksent@yahoo.com;** +23408038732062*

**Abstract**

Metaplasia is the substitution of one class of differentiated somatic cell with another differentiated somatic cell in the same tissue. It is an adaptive response to injurious agents, ranging from microbial to environmental causes.

Two classes of metaplasia have been documented in the endometrium, the more common epithelial metaplasia and the rare mesenchymal metaplasia. Both types have vast morphological forms and may occur in isolation or co-exist with one another. They are frequently overlooked and are major diagnostic pitfalls. Careful clinical and histopathological evaluation are therefore pertinent to avoid over-diagnosis or misdiagnosis. Herein, we report a rare case of cartilaginous metaplasia co-existing with endometrial gland clear cell change in a 45-year old multiparous Nigerian woman, who presented with multiple endometrial polyp.

**Keywords**: Endometrium, Metaplasia, Cartilaginous, Over-diagnosis.

**Introduction**

Metaplasia refers to a reversible transformation of one differentiated cell type to another differentiated cell type inappropriate at that site. Generally, it is an adaptive response, in which a cell type that is more sensitive to a particular stress is replaced by another cell type that can better withstand the adverse situation. Common examples of epithelial metaplasia include columnar to squamous metaplasia of the respiratory airways, excretory duct of salivary glands, and urinary bladder; and squamous to columnar metaplasia of Barrett esoghagus. Mesenchymal metaplasia are however uncommon and a typical example is myositis ossificans. Metaplasia is clinically significant because these cells are at risk of progressing from metaplasia to dysplasia and eventually to malignancy (Abbas et al., 2015).

Endometrial metaplasia is a non-neoplastic, adaptive, altered differentiated state and involves proliferation of homologous or heterogenous tissue elements, that replace the traditional endometrial stroma and glands. It occurs in response to endometrial hormonal stimulation or chronic irritation or in association with endometrial hyperplasia or malignancy. It may be epithelial or/and mesenchymal tissue elements. While epithelial metaplasia are relatively common, mesenchymal metaplasia is very rare. We therefore present the first documented case of biphasic endometrial metaplasia in Niger Delta region of Nigeria.

**Case report**

A 45-year-old Para $12^{+0}$, (12 alive) who presented with multiple polypoid masses protruding through the vulva. She subsequently under-went total abdominal hysterectomy (TAH).

The duration between the last pregnancy and hysterectomy was 3years. There was no previous history of instrumental delivery, use of intrauterine contraceptive device, dilation

and curettage. There was associated history of menorrhagia, irregular menstrual cycle and offensive vaginal discharge, but no fever or pelvic pain. There was no laboratory finding suggestive of abnormal calcium metabolism.

Hysterectomy specimen was received in the laboratory in 10% buffered Formal saline solution and consists of uterus and cervix measuring 17 x 10 x 8 cm, with multiply polypoid soft growths extending from the endometrium through the cervical os (Figure I). The endometrium shows a soft yellowish growth, which is continuous with the polypoid growths beyond the cervix (Figure II)

Histological evaluation showed that the endometrial biopsy and the biopsy of the polypoid growth are essentially the same and are composed of chronic inflammatory lesion with plasma cells, lymphocytes with fibroblasts, with occasional cartilages and metaplastic endometrial glands (Figure III & IV). A diagnosis of chronic endometritis with cartilaginous and endometrial metaplasia was made

**Discussion**

Nicolae et al., in 2010, classified endometrial metaplasia into epithelial (ciliary, tubal, mucinous, squamous, morules, and reactive changes) and stromal (osseous, cartilaginous, adipose, and smooth muscle) metaplasia. These different histological variants have been reported to be either focal or global and may be composed of homologous or heterogenous elements. They have been demonstrated less often in physiological conditions such as menstruation and pregnancy and mostly in pathological conditions such as hyperplasia, inflammation and cancer (Nicolae et al. 2011; Stringfellow 2009). In this present report, we observed both epithelial clear cell change and cartilaginous metaplasia (Figure III &IV) .

It is a general observation that metaplasia of the endometrial epithelium are relatively more common, while mesenchymal metaplasia are

very rare. The diversity in morphology of metaplastic changes in the endometrium may be explained by its inherent capacity to undergo cell renewal and turnover, which is attributed to the pluripotency of its progenitor stem cells. Like all progenitor stem cells, the endometrial stem cells are capable of differentiation into multiple cell linages, including, as in this case chondrocytes, under appropriate conditions (Nicolae et al. 2011; Ulukus, 2015).

Earlier reports have shown association of endometrial metaplasia with progesterone-coated IUCD, inflammatory lesions like chronic endometritis, benign conditions such as endometrial hyperplasia, polyps and endometriosis, and in malignant conditions like adenocarcinoma and even diverse conditions such as trauma and vitamin A deficiency. In present case, obstetric trauma and chronic endometritis are the most likely trigger (Nicolae et al. 2011; Hegmedi et al., 2007; Madiwale et al., 2001; Sethi el al.,2008).

Some authors have proposed hypercalcemia, hyperoesterinism, dystrophic calcification, and iatrogenic impactation of fetal parts as other possible mechanisms of cartilage formation in the endometrium (Madiwale et al., 2001; Sethi et al., 2008). We are however of the opinion that such metaplastic changes are likely to be associated with osseous elements, unlike in this case composed of isolated cartilaginous elements.

The presence of impacted cartilaginous tissue in the endometrium can result from retention of fetal or embryonic tissue following pregnancy termination or instrumental obstetric delivery, especially with inexperienced practitioners. Neither was the case in the index patient. Unlike cases of cartilaginous metaplasia where the islands of cartilage merge with the endometrial stroma, the retained cartilage will not show transition

to stroma on histological evaluation of retained fetal cartilaginous tissue.

Other possible differentials of heterotopic endometrial cartilaginous tissue include mesenchymal component of malignant mixed mullerian tumour (McCluggage, 2002), endometrial adenocarcinoma (Nicolae et al., 2011), and metastatic tumours with mesenchymal components such as metaplastic breast carcinoma (Sinkra et al., 2000). Presence of features of nuclear atypia or abnormal mitotic figures are important in excluding such differentials and hence avoid likely pitfall of over-diagnosis. The patient's clinical history is also very important in excluding malignant disease entities, which in this case strongly favored benign disease.

Most benign cases of endometrial cartilaginous metaplasia have been shown to be rarely associated with serious clinical consequences, although few cases associated with infertility and menorrhagia have been reported (Sangwan et al., 2015). The potential risk of malignant transformation is also a dreaded consideration, although Nicolae and co-workers reported that endometrial stromal metaplasia does not pose any cancer risk (Nicolae et al., 2011).

It is very important that the pathologist is abreast with the diverse morphological changes of endometrial metaplasia. Such knowledge will prevent misdiagnosis and overdiagnosis especially when they share morphological features of malignant lesions.

**Conclusion**

We report a case of endometrial metaplasia in a 45 year old grand multiparous Nigerian woman. Endometrial metaplasia is not uncommon in our environment. There is need to recognize and cautiously interpret such lesions to avoid diagnostic errors.



Figure I: Hysterectomy specimen with multiple polypoid growths, protruding through the cervical os



Figure II: Section through the uterus, showing that the polyp originated from the endometrium

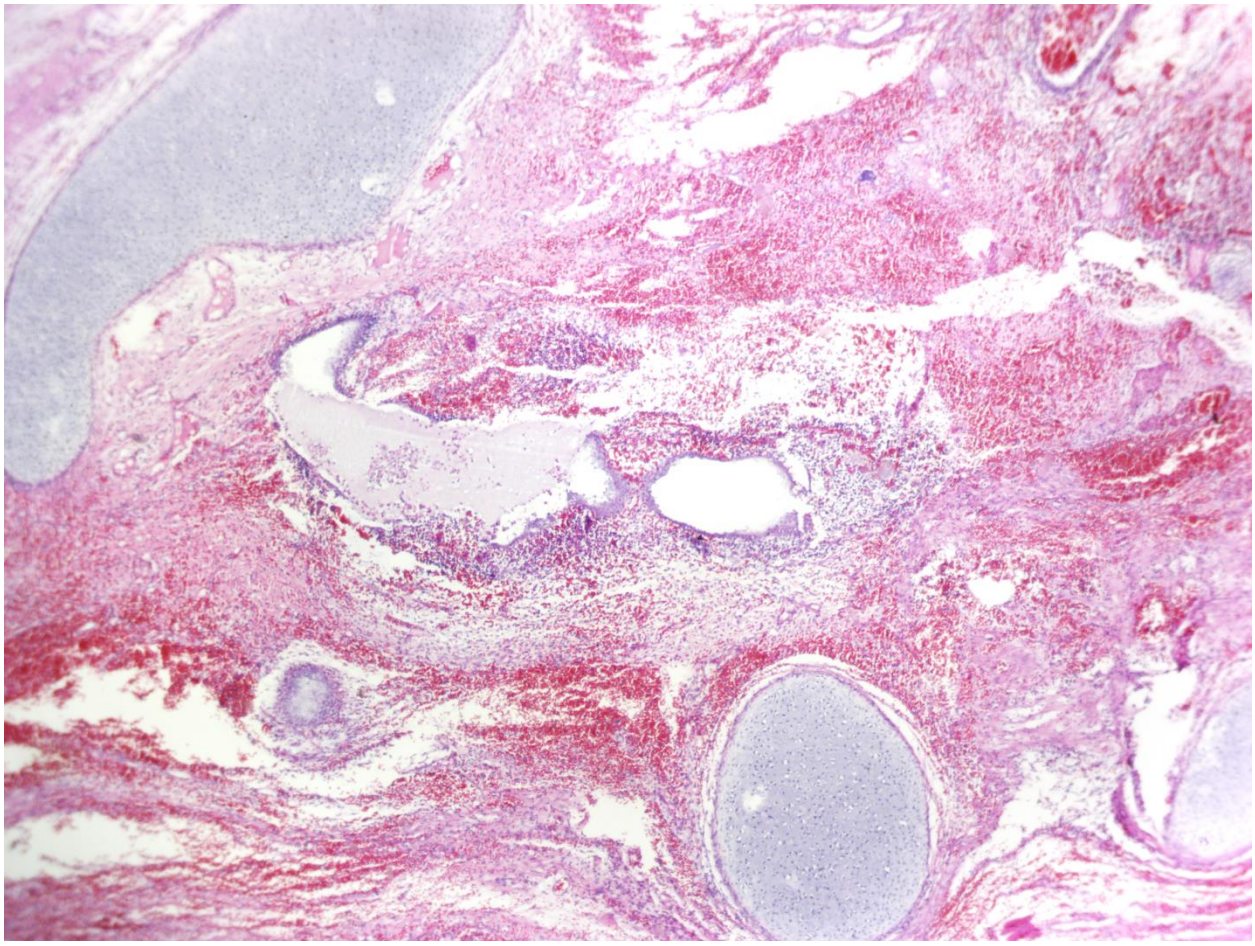

Figure III: Islands of benign cartilaginous elements in a background of chronic endometritis

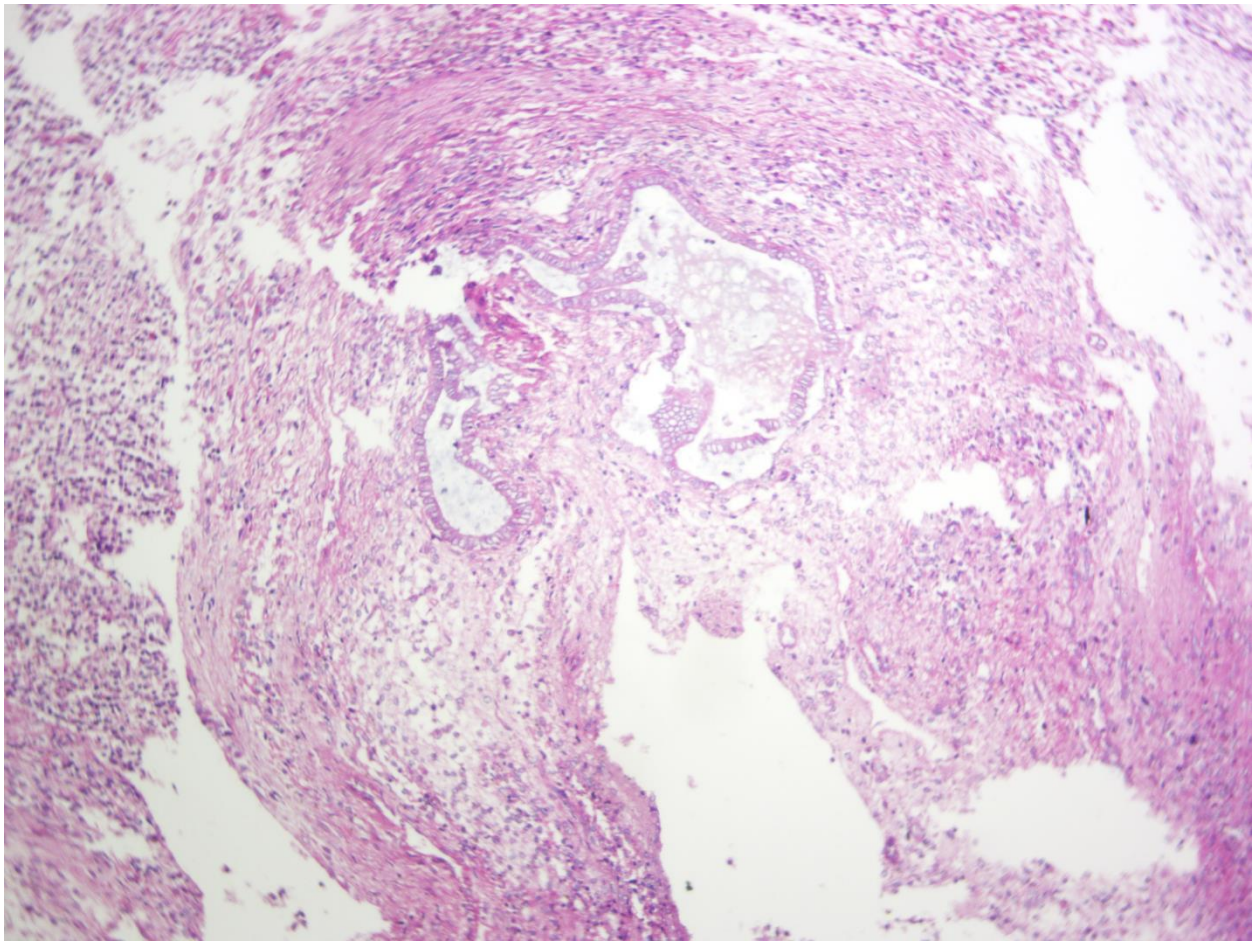

Figure IV: Atrophic endometrium with clear cell change of endometrial glands

**References**

Abbas AK, Aster JC (2015). Cell response to Stress and toxic insults: Adaptation, injury and death, In: Kumar V, Abbas AK, Aster JC editors. Robbins and Cotran Pathologic basis of Disease. 9ed. Elsevier, Philadedelphia. p. 37-38.

simone CO (2012). Molecular Biology of respiratory syncytial viruses, In: Charles OE, Okechukwu CE editors. Synopsis of Human Viral Infections. University Press, Awka, p. 83-95.

Hejmedi R, Chaudri S,Ganesan R, Rollason TP (2007): Morphologic Changes in the Endometrium Associated With the Use of the Mirena Coil: A Retrospective Study of 106 Cases. International J Surg Pathol. 15(2). 148-54.

Madiwale C, Dahanuka S (2001): Heterotopic uterine cartilage. J Postgrad Med. 47. 281.

McCluggage WG (2002): Malignant biphasic uterine tumours: carcinosarcomas or metaplastic carcinomas?. J Clin Pathol. 55(5). 321–325.

Nicolae A, Preda O, NogalesFF (2011): Endometrial metaplasias and reactive changes: a spectrum of altered differentiation. J. Clin. Pathol. 64. 97-106.

Sangwan VG, Sangwan M, Mahendroo R et al (2015): Nulligravida Female with Heterotopic Cartilage in Uterus: A Case Report with Historical Review. Journal of Gynecologic Surgery. 31(4). 220-223.

Sethi S, Bhatnagar S, Sethi S (2008): Heterotopic chondroid tissue in the uterus. Indian J Pathol Microbiol. 51. 568-9

Sinkra P, Milchgrub S, Miller SD, Albores-Saavedra J,Hameed A (2000): Uterine Metastasis from a

Heterologous Metaplastic Breast Carcinoma Simulating a Primary Uterine Malignancy. Gynecologic Oncology. 77(1). 216-8.

Stringfellow HF (2009): Pathology of the Uterus and Fallopian tube. Diagnostic Histopath. 15(12). 564-70.

Ulukus M (2015): Stem cells in endometrium and endometriosis. Women's Health. 11(5). 587–95.