Effects of sub-chronic oral administration of hydromethanolic stem extract of Costus afer Ker Gawl. (Costaceae) on body weight, relative organ weight (ROW) and histopathology of selected organs in rats

AbdulFatai Adetunji Jimoh[1*], Bilkisu Bello Maiha[2], Ben Ahmed Chindo[1], Janet Ifekanwa Ejiofor[2], Musa Itopa Yakubu[1]

[1]Department of Pharmacology and Toxicology, Faculty of Pharmaceutical Sciences, Kaduna State University, Kaduna. Nigeria.
[2]Department of Pharmacology and Therapeutics, Faculty of Pharmaceutical Sciences, Ahmadu Bello University, Zaria,Nigeria.

Submitted: 26th Dec., 2022; Accepted: 14th July., 2023; Published online: 31st Aug., 2023
DOI: https://doi.org/10.54117/jcbr.v3i4.1
**Corresponding Author: AbdulFatai Adetunji Jimoh; abdulfataijimoh@gmail.com / abdulfatai.jimoh@kasu.edu.ng; +234(80) 37015285*

Abstract

Adverse effects of plant extracts on body weight, relative organ weight and histopathology are important indicators of toxicity. The aim of this study was to evaluate the acute and sub-chronic toxicity of the hydromethanolic stem extract of *Costus afer* Ker Gawl. (Costaceae). OECD (2008) Guideline 425 was used to evaluate oral acute toxicity of the extract. Sub-chronic oral administration of the extract on body weight, relative organ weight (ROW) and histopathology of selected organs in Wistar rats were evaluated using OECD 1995 guideline 407. Forty *Wistar* rats of both sexes were divided into 4 groups. Rats in control group (Group I) received 1 ml/kg/day distilled water while Groups II, III and IV rats received 250, 500, and 1000 mg/kg/day of the extract respectively for 28 days. All treatments were administered orally. The rats were sacrificed under light halothane anaesthesia on the 29th day and the target organs were harvested, weighed and examined macroscopically for any morphological changes and microscopically for any lesions. There were no significant changes in mean body weights of rats and relative organ weights of selected organs in the extract treated groups when compared with the control group (distilled water). Although histological features of the brain, heart, stomach mucosa, lungs, spleen, ovaries and uterus in the extract treated groups were similar to those of control, slight to moderate renal and hepatic necrosis and necrosis of secondary spermatogenic cells at doses of 500 mg/kg and above of the extract were observed in the kidneys, liver and testes respectively. Caution should be exercised on sub-chronic administration of this extract as it may be toxic to the kidneys, liver and testes.

Keywords: Body weight, *Costus afer*, Histopathology, Relative Organ Weight, Rats

Introduction

Across the world, traditional medicine (TM) is either the mainstay of health care delivery or serves as a complement to it (WHO 2013b). Although traditional medicines are generally said to be safe, they are not without side effects, especially as they are often used for a long period of time to treat chronic diseases. It is therefore important to study the toxicological effects of such medicines with a view to providing safe and effective medicines of herbal sources.

Costus afer Ker Gawl is one of 150 species of tall, perennial and rhizomatous herbs of the order *Zingiberale*, family *Costaceae*, genus *Costus* and species *afer* (Edeoga and Okoli, 2000). The common name is ginger lily or bush sugar cane and it is known as *Ireke omode* in Yoruba, *Kakizuwa* in Hausa, *Okpete* or *Okpoto* in Igboland, and *Mbritem* in Efik (Iwu and Anyawu, 1982; Anaga *et al.,*2004). Traditional uses of the plant include treatment of diabetes mellitus, inflammation and arthritis (Soladoye and Onyesika, 2008), cough, malaria, veneral diseases and skin eruptions (Okoko,2009). The plant is used in Nigeria as fodder to treat goats with retained placenta and whole boiled root is applied to cuts and sores (Awouters *et al*., 1978). A rhizome decoction or the raw rhizome have been reportedly used to treat leprosy and venereal diseases while the leaf sap is used as eye drops and nose drops to treat headache, vertigo, oedema and fever (Ezejiofor *et al*., 2013). In Gabon, the stem sap is rubbed on the body to treat colic (Aweke, 2007).

An extensive literature search revealed a large number of pharmacological studies carried out using various parts of *Costus afer* herb with significant *in vitro* antibacterial and amoebicidal activities (Lin *et al*., 1996), *in vitro* antioxidant activities (Taiwo and Bolanle, 2003), local anaesthetic and antihyperglycemic activities (Anaga *et. al*., 2004; Aweke, 2007;) and abortificient property at 3rd trimester of pregnancy (Guzman and Guerrero, 2002; Anaga *et al*., 2004). There are a few studies on the toxicological effects of *Costus afer* in literature. The hepatoprotective effect of methanolic extract of *Costus afer* stem has been reported (Ukpabi *et al*., 2012; Tonkiri *et al*., 2015). However, the aqueous leaf extract of *Costus afer* was reported to be hepatotoxic but non-toxic to the kidneys of male albino rats (Ezejiofor *et al.,* 2013). Udem and Ezeasor (2010) reported decreases in the PCV, haemoglobin concentration (Hb) and total RBC counts in mice treated with aqueous leaf and stem bark extract of *Costus afer* when compared with the control (distilled water). The wide use of this plant in ethnomedicine and the scanty information available on its toxicity profile necessitated further evaluation of the effect of hydromethanolic stem extract of *Costus afer* on body weight, relative organ weight and the histopathology of some selected organs following sub-chronic administration.

Materials and Methods

Materials and reagents

Eosin stain (BDH Ltd, Poole, England), Formalin (BDH Ltd, Poole, England), Haematoxylin stain (BDH Ltd, Poole, England), Halothane (Primal Healthcare Ltd, India), Methanol A.R (JHD, China) were used for this investigation.

Equipment

Avery balance (W and T, Avery Ltd, Birmingham, England), Dry Oven (DHG-9030), Rotary Evaporator (Searchtech Instruments, England. RE 52-3), Water bath (Model DK-420, NO L-606382). Rotary Evaporator (Searchtech Instruments, England. RE 52-3), Rotary Microtone (RM 2125, Leica Microsystem, Germany) were the equipment used for the experiments.

Methods

Preparation of the extract

The powdered stem of *Costus afer* weighing three hundred grammes (300 g) was macerated with 1.8 L 70% v/v methanol at room temperature for 72 hours with occasional stirring with a glass rod. The mixture was filtered with a clean muslin cloth, followed by Whatman No 1 filter paper to remove all debris. The filtrate was then concentrated in a rotary evaporator (Searchtech Instruments, England. RE 52-3) at 45°C and under reduced pressure. The residue obtained was dried in an oven at 45°C. The percentage yield of the dried extract was calculated as follows;

% Yield

$$= \frac{weight\ of\ dried\ extract}{weight\ of\ powdered\ plant\ material}\ x\ 100$$

Phytochemical Analysis of the Hydromethanolic Stem Extract of *Costus afer* and its Residual Aqueous Fraction

The methods of Trease and Evans (2004) and Sofowora (1993) were used to screen for the presence or absence of alkaloids, flavonoids, saponins, tannins, glycosides, carbohydrates, steroids/triterpenes and anthraquinones.

Acute Toxicity Study in Rats

The acute toxicity study of the hydromethanolic stem extract of *Costus afer* (HMECA) was carried out using OECD (2008) Guideline 425: Up - and- Down Procedure. Female nulliparous and non-pregnant rats were used and their weights fell within the interval of ± 20% of the mean weight of the sample population obtained. The rats were obtained from the Animal House Facility, Department of Pharmacology and Therapeutics, Ahmadu Bello University, Zaria. They were housed individually in plastic cages in the laboratory at ambient temperature and humidity and 12 hours light and 12 hours darkness. The rats were fed with standard feed (Vital Feeds, Jos) and water *ad libitum*. They were kept in their cages for at least 5 days prior to dosing to allow for acclimatization to laboratory conditions.
The rats were deprived of food for 3 – 4 hours prior to dosing, but they were given water *ad libitum*. The rats were then weighed and the extract was administered orally in a single dose according to the body weight obtained after fasting. After the extract was administered, food (and not water) was withheld for another 1 – 2 hours.

The extract was prepared shortly prior to administration to ensure the stability of the preparation. Limit test doses of 5000 mg/kg body weight was used in the experiments. One rat was dosed at 5000 mg/kg orally and it was observed for signs and symptoms of toxicity, as well as mortality for the first 4 hours and over a period of 24 hours. The animal survived after 24 hours, then 2 rats were dosed at the limit test dose of 5000 mg/kg and also observed for signs and symptoms of toxicity and mortality over a period of 24 hours. The 2 rats did not show any signs and symptoms of toxicity and there was no death. The limit test was therefore terminated.

Sub-chronic toxicity

OECD (1995) Guidelines 407 sub-chronic oral toxicity test method in rats was used in this study. Forty (40) *Wistar* rats of both sexes (20 males and 20 females) with an average weight of 180 g, were randomized and divided into 4 groups of 10 rats each (5 males and 5 females, kept in separate cages based on sex). Group I (Control) received distilled water 1ml/kg body weight orally daily for 28 days. Groups II, III and IV were administered 250, 500 and 1000 mg/kg body weight of the extract respectively daily for 28 days. The rats had free access to food and water during the duration of the study and they were observed daily for general symptoms of toxicity (hyperactivity, sedation and salivation) and mortality. The rats were weighed once weekly and the average change in weight calculated. On the 28th day of the experiment, the rats were starved of food (and not water) overnight. The rats were sacrificed under light halothane anaesthesia on the 29th day and the brain, heart, stomach, lungs, spleen, uterus, ovaries, testes, kidneys and liver were harvested, weighed and examined macroscopically. The organs were preserved in 10% formalin prior to histological examination.

Relative organ weight and histology

Bancroft *et al*., (2018) histological methods were used and the experiments were carried out in the Histology Unit, Department of Anatomy, Ahmadu Bello University, Zaria, Nigeria**.** The harvested organs were weighed and carefully examined macroscopically for gross pathological changes. Relative organ weight was calculated by expressing absolute organ weight as a percentage of total body weight. Cold solution of formalin (10%) was used to fix the organs for 48 hours. Thereafter, the tissues were dehydrated by passing them through ascending grades of methanol from 70% to 90% and 100% for 12 hours. The tissues were then cleared in xylene for 2 hours, infiltrated and embedded in liquid paraffin. The tissues were cut using Rotary Microtome (RM 2125, Leica Microsystem, Germany) at 5 micron thickness and the sections were stained using haematoxylin and eosin staining technique. The tissues were examined microscopically for pathological lesions such as infiltration of lymphocytes into portal and central veins, mucosal atrophy, presence of inflammatory cells on the wall, eosinophils, lymphocytes and plasma cells. Photomicrographs were taken at x 250 magnification.

Ethical approval

All experiments were carried out in accordance with the Guidelines and Principles of the Ahmadu Bello University Committee on Animal Use and Care (Approval Number: ABUCAUC/2018/015).

Statistical Analysis

All quantitative data were expressed as mean ± standard error of mean and presented as tables. Other results were presented as plates. Quantitative data were analysed using One Way Analysis of Variance (ANOVA) followed by Bonferroni post hoc multiple comparisons test using SPSS Version 20 (2011) software package-values less than or equal to 0.05 ($p \leq 0.05$) were considered significant.

Results

The macerated 300 g of the powdered stem of *Costus afer* yielded 15.6 g of hydromethanolic extract (5.2% yield). Qualitative phytochemical screening of the extract revealed the presence of saponins, tannins, carbohydrates, flavonoid, alkaloid and hydroxyanthraquinones. Cardiac glycosides, cyanogenic glycosides, steroids and triterpenes were absent.

All the rats that were administered with the stem extract did not show any signs of toxicity and death in the first four hours of administration and over a period of 24 hours in the first and second stages of the acute toxicity test. The median oral lethal dose in the rats was estimated to be greater than 5000 mg/kg. No physical and clinical signs of toxicity were observed in the rats throughout the 28-day period of the study. However, 3 rats died within the period of the study in the extract treated groups (500 mg/kg dose – 1 rat, 1000 mg/kg dose – 2 rats) and 2 rats died in the control (distilled water) group. There were no significant changes in mean body weights of rats at all the doses of the extract tested as compared to the control group as decreases in mean weights ranged between -1.6% and -4.5% in the first 3 weeks of the study (Table1). However, mean body weights in all the extract treated groups increased by between +3.1% and +14.9% in week 4 of the experiment when compared with the control. All the extract treated groups and the control group of rats gained weight at the end of the 28 days period of the study ranging from +4.7% for the control group to +21.5% for the 500 mg/kg extract group (Table 1)

The mean relative organ weights of the brain, heart, stomach, lungs, spleen, uterus, ovaries and testes in the extract treated groups were not significantly different ($p>0.05$) from that of the control (distilled water) group (Table 2).

Macroscopical examination of all the organs revealed no gross histopathologic changes. Microscopic examination of tissue sections showed no visible histopathologic changes in brain tissues at 250 and 500 mg/kg doses of the extract but vacuolation and neuronal necrosis was observed at 1000 mg/kg dose of the extract (Plate I). All the doses of the extract tested showed no visible histopathologic changes in cardiac tissues, stomach mucosa, spleen, uterus and ovaries (Plates II, III, V, VI and VII). Slight alveoli necrosis was observed in the lungs of rats at 1000 mg/kg dose of the extract (Plate IV). The extract at 250 mg/kg dose showed normal seminiferous tubules similar to those in the control (distilled water) group but necrosis of secondary spermatogenic cells was observed at higher doses of 500 and 1000 mg/kg of the extract (Plate VIII). Slight tubular necrosis was observed at all doses of the extract tested (Plate IX). The effect on the liver increased with increase in dose of the extract: There was vascular congestion with lymphocyte hyperplasia at the lowest dose of 250 mg/kg, slight hepatic necrosis at 500 mg/kg dose while moderate hepatic necrosis was observed at the highest dose of 1000 mg/kg (Plate X)

Table 1: Effect of 28 Days Repeated Oral Administration of Hydromethanolic Stem Extract of *Costus afer* on Body Weights of Rats

Time	Distilled water 1 ml/kg/day (g)	HMECA 250 mg/kg/day (g)	HMECA 500 mg/kg/day (g)	HSECA 1000 mg/kg/day (g)
Day 0	177.80 ± 8.06	178.90 ± 8.34	176.10 ± 8.55	181.30 ± 9.3
Week 1	177.30 ± 9.06	186.90 ± 9.91	169.40 ± 9.09	174.40 ± 10.99
Week 2	197.6 ± 10.03	189.80 ± 11.15	183.10 ± 10.79	191.56 ± 12.49
Week 3	199.28 ± 13.00	189.80 ± 11.33	197.11 ± 7.71	189.11 ± 14.86
Week 4	186.17 ± 2.75	201.78 ± 11.04	214.00 ± 8.74	191.89 ± 17.26
% Change in Weight after 28 days	+ 4.7	+ 12.8	+ 21.5	+ 5.8

Values are means ± S.E.M, n = 10, One Way ANOVA, $p > 0.05$ = No significant difference between mean body weights in extract treated groups and control (distilled water), HMECA = Hydromethanolic stem extract of *Costus afer*.

Table 2: Effect of 28 Days Repeated Oral Administration of Hydromethanolic Stem Extract of *Costus afer* on Relative Organ Weights (R.O.W) in Rats

ORGAN	Distilled water 1 ml/kg/day	HMECA 250 mg/kg/day	HMECA 500 mg/kg/day	HMECA 1000 mg/kg/day
Lungs	1.09 ± 0.20	0.96 ± 0.11	1.06 ± 0.21	1.11 ± 0.43
Liver	3.87 ± 0.25	3.81 ± 0.09	4.08 ± 0.27	4.02 ± 0.33
Kidney	0.60 ± 0.06	0.64 ± 0.03	0.68 ± 0.06	0.71 ± 0.08
Stomach	1.23 ± 0.21	1.03 ± 0.11	1.16 ± 0.10	1.17 ± 0.31
Spleen	0.39 ± 0.05	0.46 ± 0.07	0.45 ± 0.06	0.50 ± 0.04
Heart	0.41 ± 0.04	0.37 ± 0.01	0.39 ± 0.02	0.39 ± 0.04
Uterus	0.91 ± 0.26	0.95 ± 0.27	1.13 ± 0.33	1.20 ± 0.35
Testes	1.36 ± 0.40	1.75 ± 0.52	1.19 ± 0.35	1.37 ± 0.39
Brain	0.88 ± 0.12	0.76 ± 0.04	0.80 ± 0.08	0.89 ± 0.08

Values are means ± S.E.M, n = 10, One Way ANOVA, $p > 0.05$ = No significant difference between the mean R.O.W in extract treated groups and control (distilled water), HMECA = Hydromethanolic stem extract of *Costus afer*.

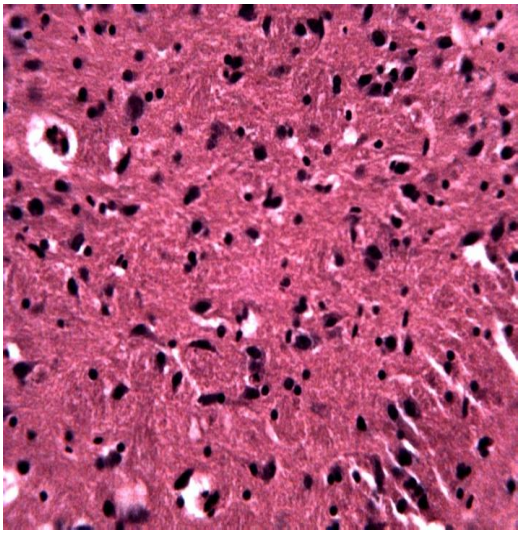

1

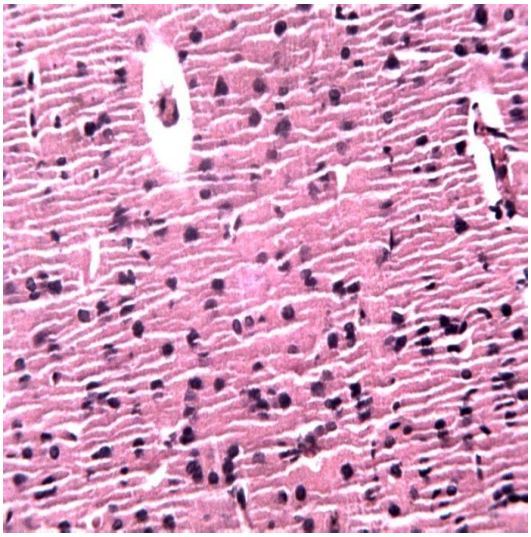

2

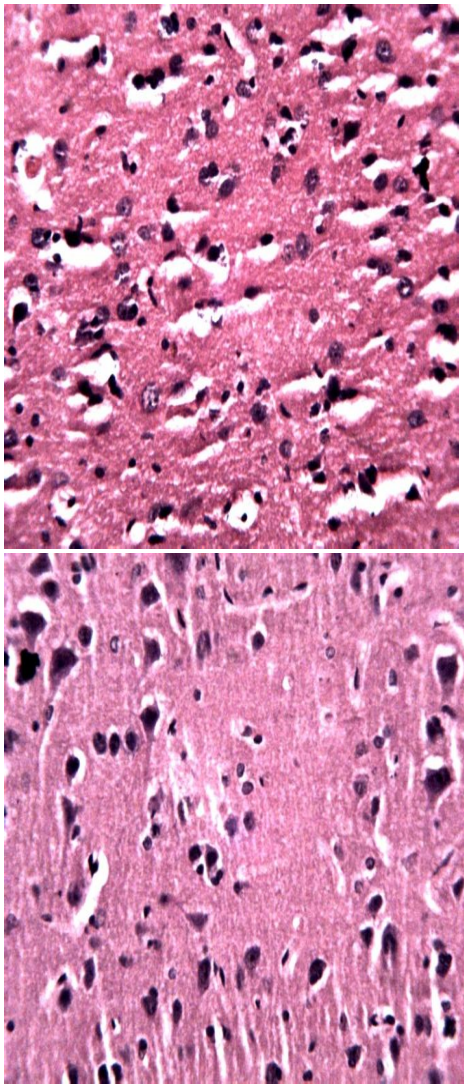

Plate I: Photomicrographs of the brain in rats administered with 250, 500 and 1000 mg/kg of the hydromethanolic stem extract of *Costus afer* compared with Control (Distilled water) H and E stain (x 250 magnification)

1 = Distilled water, 2 = 250 mg/kg extract, 3 = 500 mg/kg extract showing normal cardiac features
and 4 = 1000 mg/kg extract blue arrow showing slight vacuolation (V), and neuronal necrosis (NN).

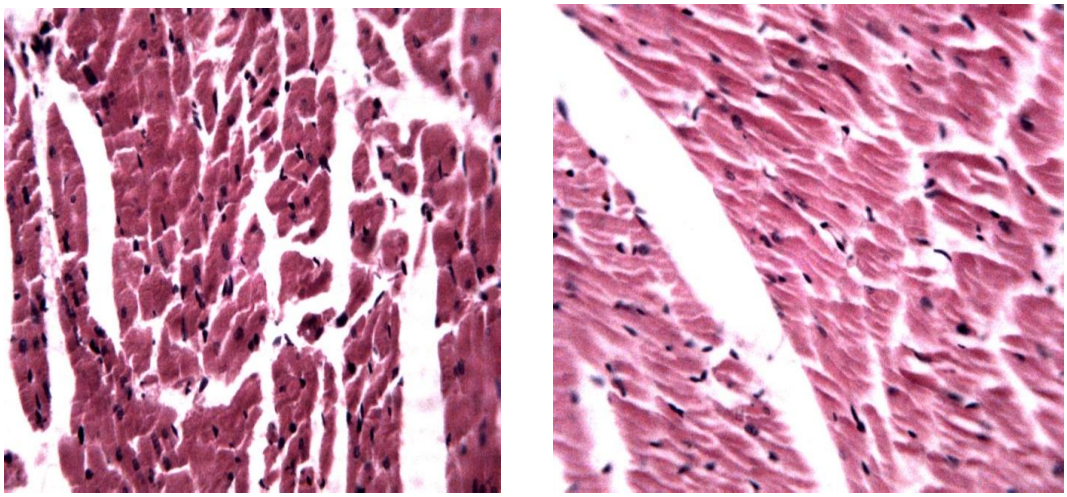

1 2

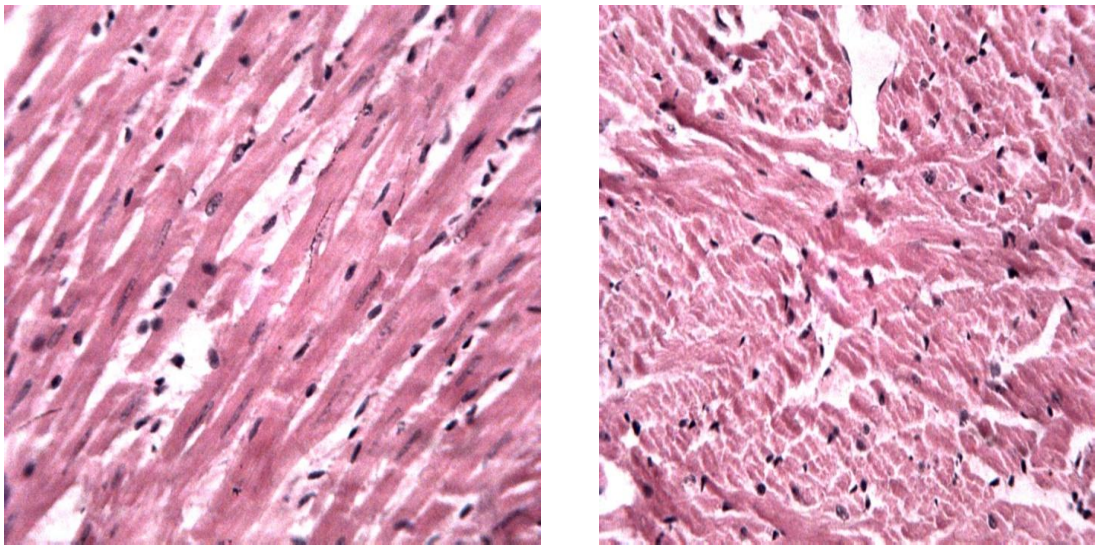

3 4

Plate II :Photomicrographs of the heart in rats administered with 250, 500 and 1000 mg/kg of the hydromethanolic stem extract of *Costus afer* compared with control (Distilled water) H and E stain (x 250 magnification)

1 = Distilled water, 2 = 250 mg/kg extract, 3 = 500 mg/kg extract and 4 = 1000 mg/kg extract, all showing normal cardiac tissues

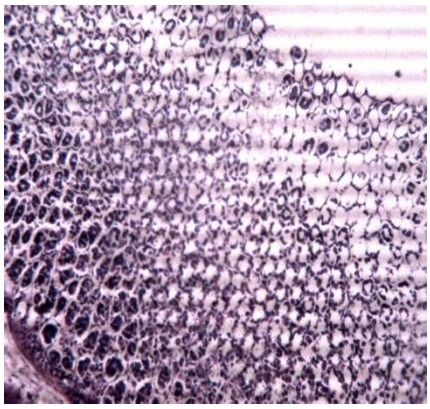

1

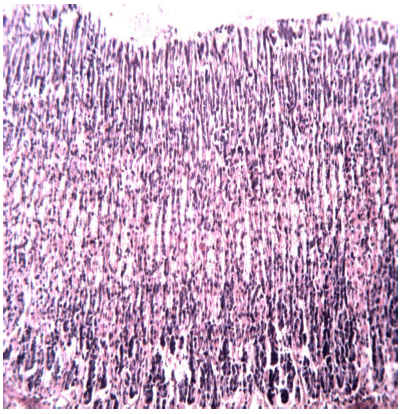

2

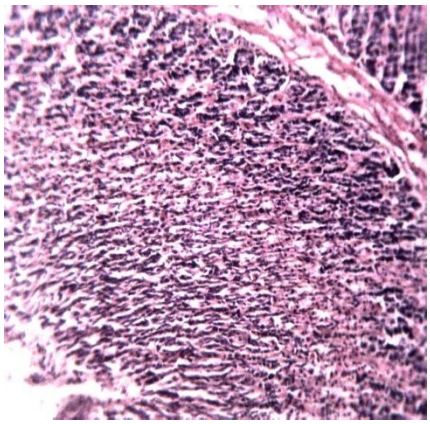

3



4

Plate III: Photomicrographs of the stomach of rats administered with 250, 500 and 1000 mg/kg of the hydromethanolic stem extract of *Costus afer* compared with control (Distilled water) H and E stain (x 100 magnification)

1 = Distilled water showing normal stomach mucosa
2 = 250 mg/kg extract, 3 = 500 mg/kg extract and 4 = 1000 mg/kg extract all showing normal stomach mucosa

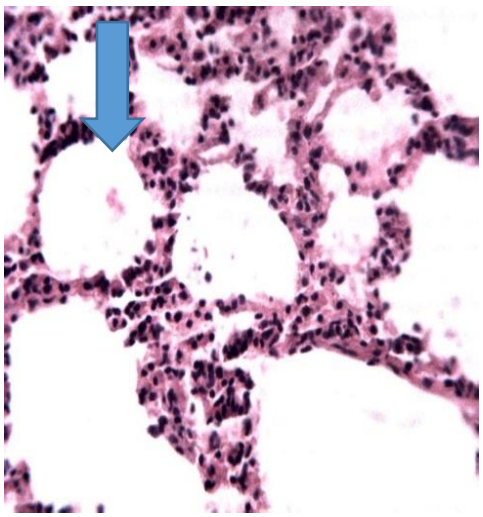

1

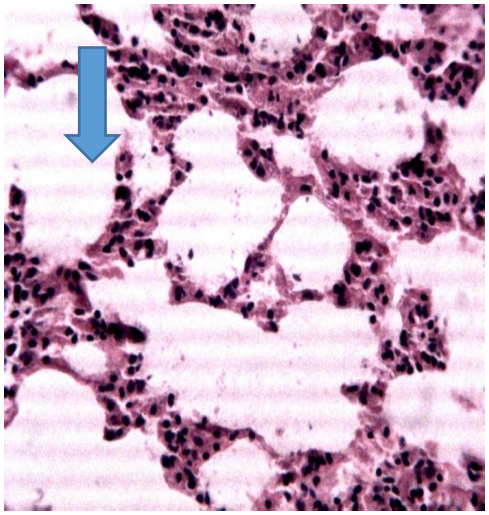

2

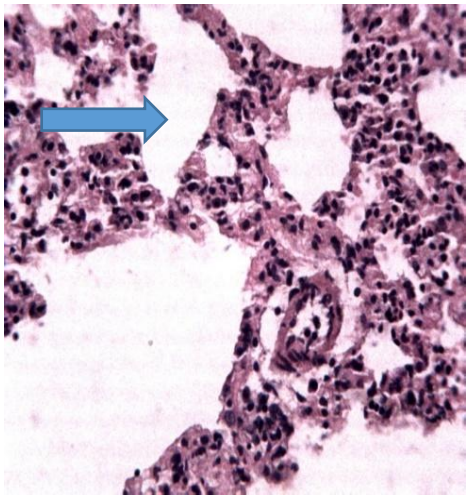

3

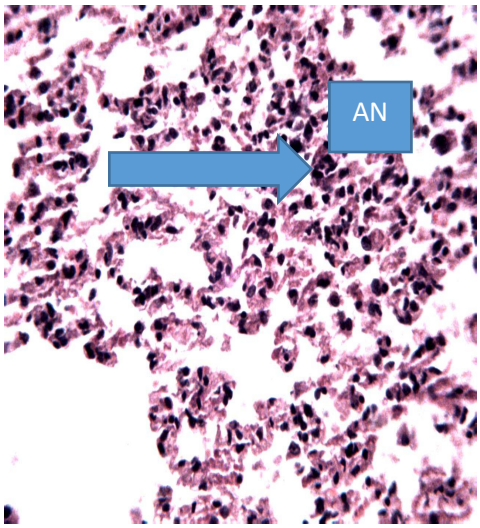

4

Plate IV: Photomicrographs of the lungs of rats administered with 250, 500 and 1000 mg/kg of the hydromethanolic stem extract of *Costus afer* compared with control (Distilled water) H and E stain (x 250 magnification)

1 = Distilled water showing normal alveoli
2 = 250 mg/kg extract, 3 = 500 mg/kg extract, blue arrows showing normal alveoli and 4 = 1000 mg/kg extract, blue arrow showing slight alveoli necrosis (AN)

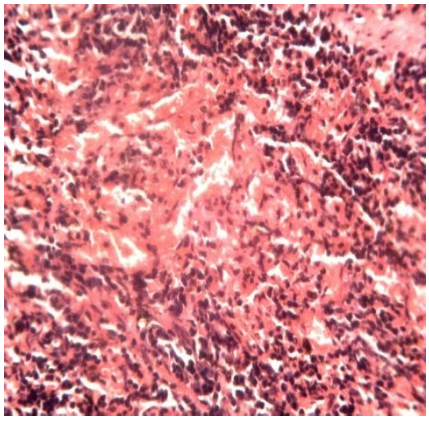

1

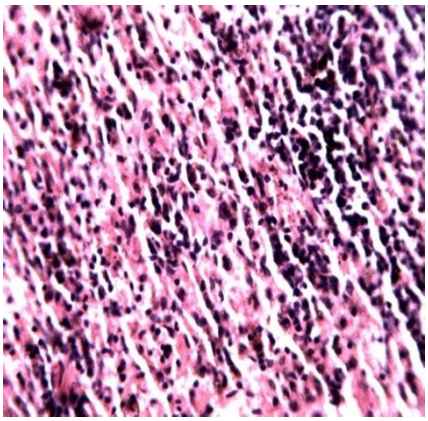

2

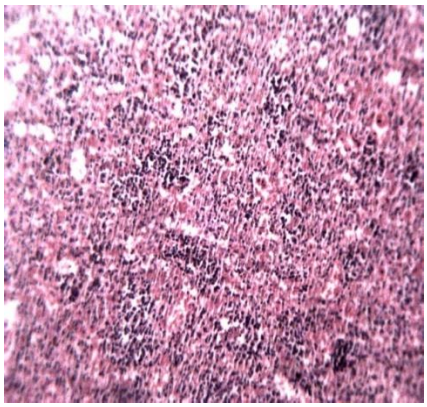

3

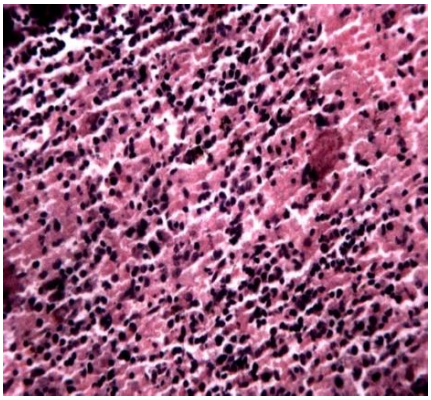

4

Plate V: Photomicrographs of the spleen of rats administered with 250, 500 and 1000 mg/kg of the hydromethanolic stem extract of *Costus afer* compared with control (Distilled water) H and E stain (x 250 magnification).

1 = Distilled water showing normal Red pulp (R) and White pulp (W) distribution
2 = 250 mg/kg extract, 3 = 500 mg/kg extract) and 4 = 1000 mg/kg extract, all showing normal Red (R) and White pulp (W) distribution

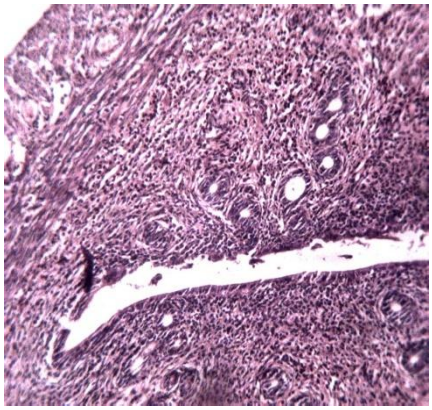

1

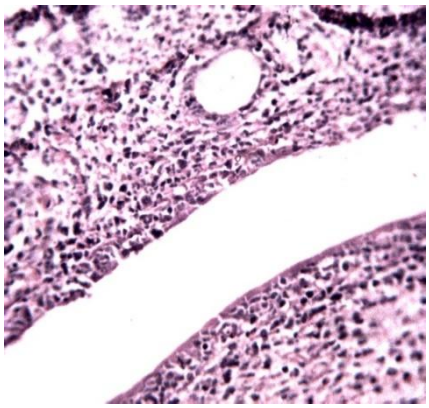

2

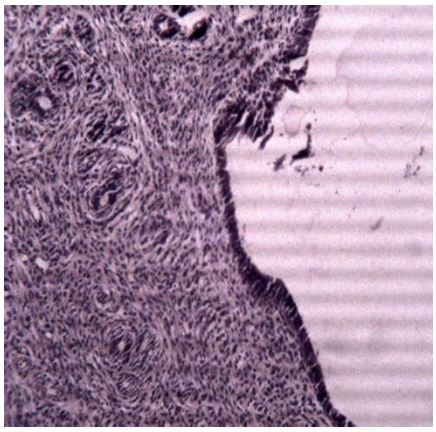

3



4

Plate VI: Photomicrographs of the uterus of rats administered with 250, 500 and 1000 mg/kg of the hydromethanolic stem extract of *Costus afer* compared with Control (Distilled water) H and E stain (x 250 magnification).

1 = Distilled water showing normal uterine tissue
2 = 250 mg/kg extract showing normal uterine tissue
3 = 500 mg/kg extract showing normal normal uterine tissue
4 = 1000 mg/kg extract showing normal uterine tissue

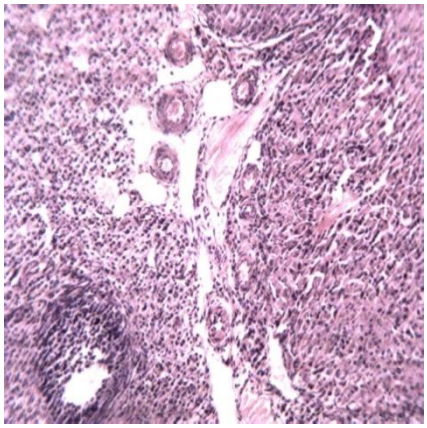

1

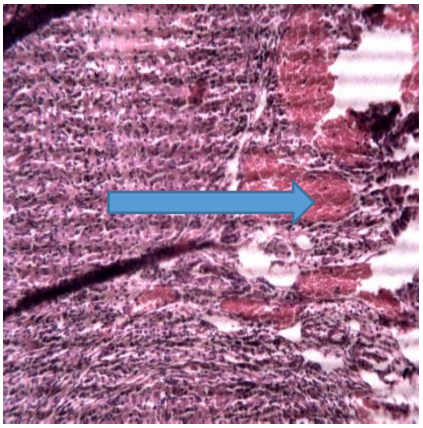

2

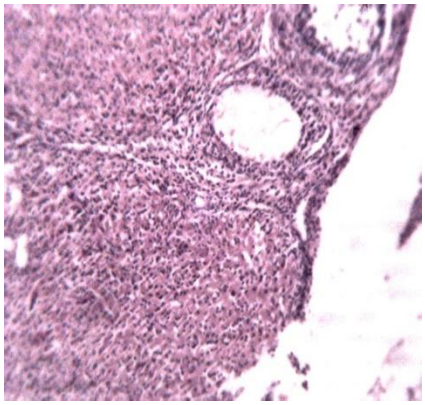

3

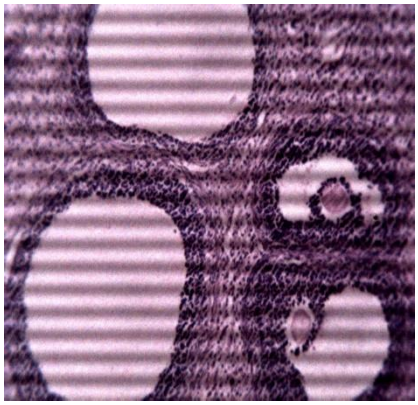

4

Plate VII: Photomicrographs of the ovaries of rats administered with 250, 500 and 1000 mg/kg of the hydromethanolic stem extract of *Costus afer* compared with control (Distilled water) H and E stain (x 250 magnification).

1 = Distilled water showing normal ovarian tissue
2 = 250 mg/kg extract, blue arrow showing marked increase in corpus luteum (CL)
3 = 500 mg/kg extract showing normal ovarian tissue
4 = 1000 mg/kg extract showing normal ovarian tissue

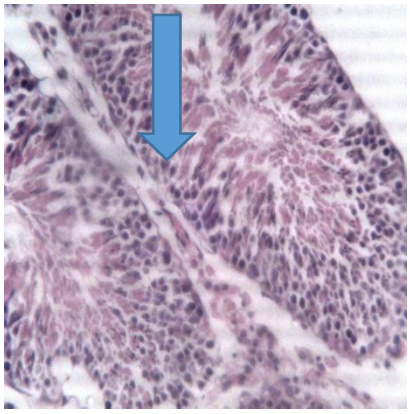

1

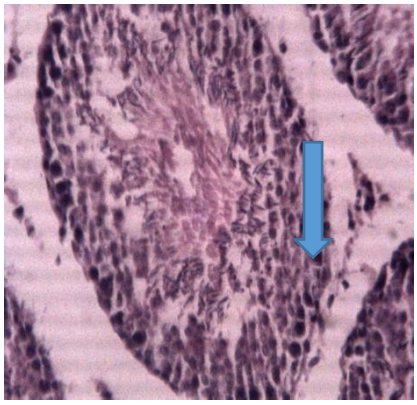

2

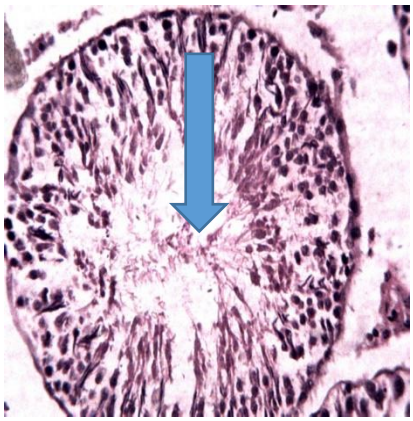

3



4

Plate VIII : Photomicrographs of the testes of rats administered with 250, 500 and 1000 mg/kg of the hydromethanolic stem extract of *Costus afer* compared with control (Distilled water) H and E stain (x 250 magnification).

1 = Distilled water, blue arrow showing normal seminiferous tubules
2 = 250 mg/kg extract, blue arrow showing normal seminiferous tubules (ST)
3 = 500 mg/kg extract, blue arrow showing necrosis of secondary spermatogenic cells (SN)
4 = 1000 mg/kg extract, blue arrow showing necrosis of secondary spermatogenic cells (SN)

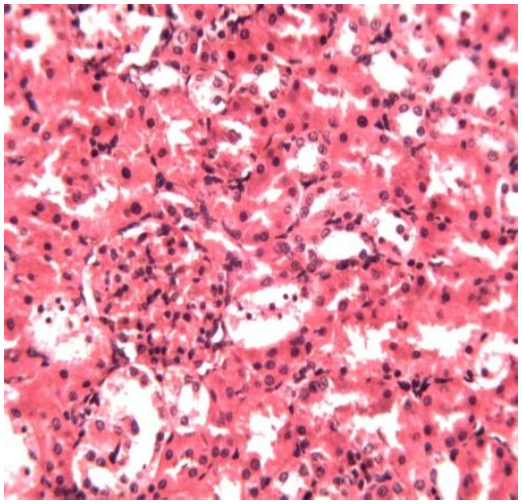

1

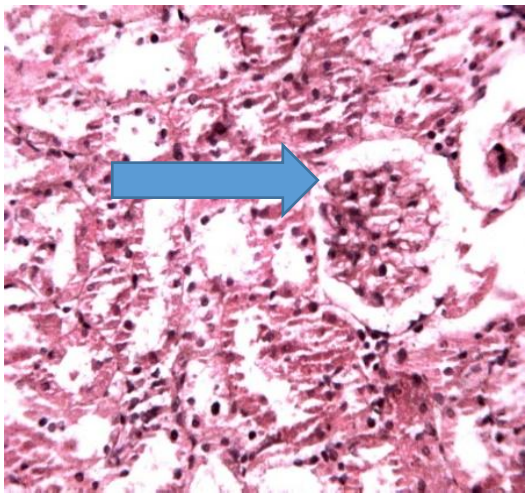

2

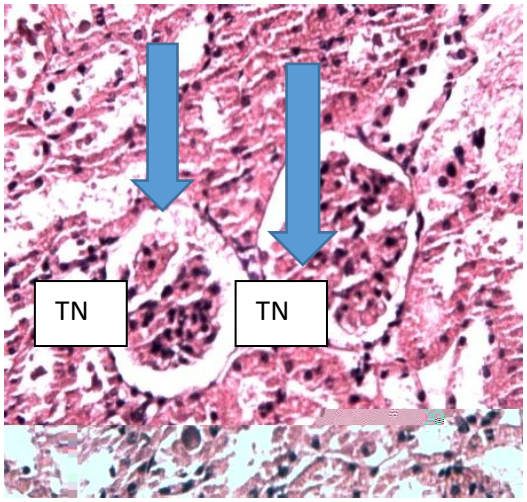

3

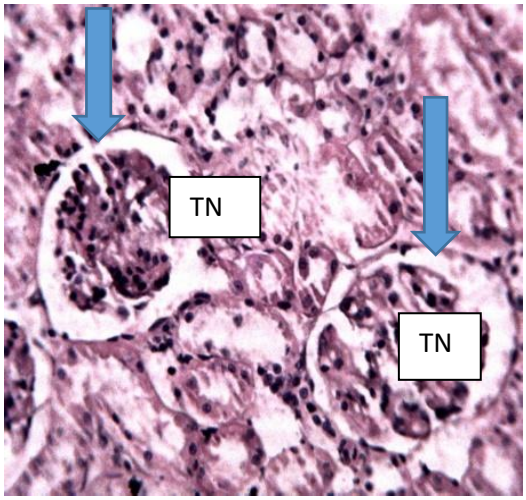

4

Plate IX: Photomicrographs of the kidneys of rats administered with 250, 500 and 1000 mg/kg of the hydromethanolic stem extract of *Costus afer* compared with control (Distilled water) H and E stain (x 250 magnification)

1 = Distilled water showing normal glomeruli (G) and normal tubules (T)
2 = 250 mg/kg extract, 3 = 500 mg/kg extract and 4 = 1000 mg/kg extract, blue arrows showing slight tubular necrosis (TN)

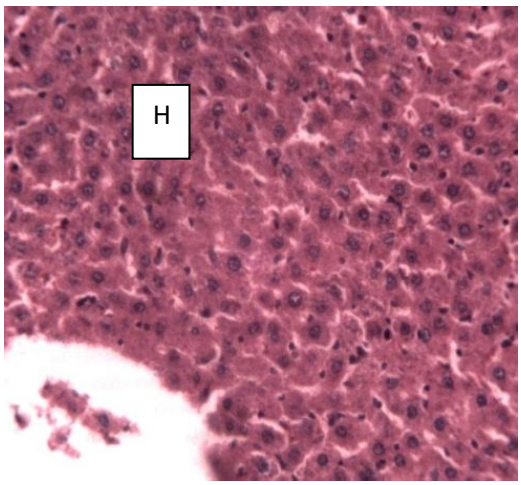

1

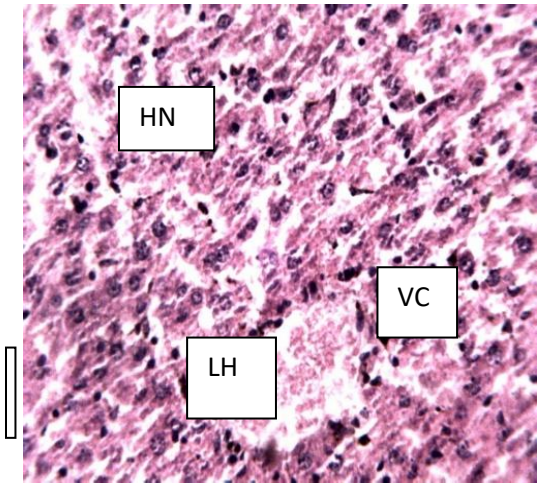

2

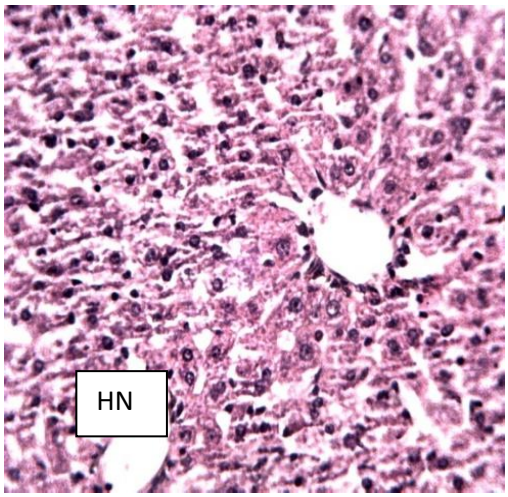

3

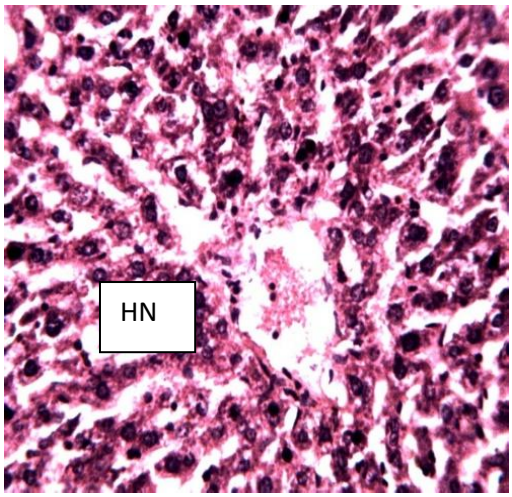

4

Plate X: Photomicrographs of the liver of rats administered with 250, 500 and 1000 mg/kg of the hydromethanolic stem extract of *Costus afer* compared with control (Distilled water) H and E stain (x 250 magnification

1 = Distilled water showing normal hepatocytes (H)
2 = 250 mg/kg extract showing vascular congestion (VC) with lymphocyte hyperplasia (LH) and slight hepatic necrosis (HN), 3 = 500 mg/kg extract showing slight hepatic necrosis (HN), 4 = 1000 mg/kg extract showing moderate hepatic necrosis (HN)

Discussion

The acute toxicity study did not produce any death at a dose of 5000 mg/kg body weight. This indicated that the hydromethanolic stem extract of *Costus afer* is relatively safe for use. In the sub-chronic toxicity study that lasted 28 days no physical and/or clinical signs of toxicity were observed. However, some deaths were recorded in the extract treated and control (distilled water) groups and these deaths are likely due to natural causes rather than the effect of the extract as some deaths were also observed in the distilled water control group.

The body weights of rats and relative organ weights (ROW) of selected organs in rats treated with various doses of the extract were not significantly different ($p>0.05$) from those of the control group (distilled water).This result is similar to that of Udem and Ezeasor (2010) who also reported no significant changes ($p> 0.05$) in the body weights of mice after subchronic administration of aqueous leaf and stem bark extract of *Costus afer* in mice when compared to the mean weight of mice in the control group. Generally, there were increases in body weights of rats that ranged from +3.1% and +14.9% in the extract treated groups after 28 days of repeated oral administration of the extract as compared to the control group. An increase in weight of the rats after 28 days of administration of the extract may mean that feeding and utilization of protein and other nutrients were not affected by the extract and in effect the metabolic processes may not have been affected (Bidhe and Ghosh, 2004). Change in body weight is a marker of adverse effects of drugs and it is considered statistically significant if body weight loss is more than 10% (Teponigning *et al*., 2018).The result of this study indicated that the hydromethanolic stem extract of *Costus afer* did not significantly ($p>0.05$) affect the body weights of rats at all the doses tested when compared with the control (distilled water) group because the decline in body weights observed in the first 3 weeks of the study were less than 10%. Furthermore, on day 28 (week 4), increase of between +3.1% and 14.9% was recorded in the extract treated groups when compared to the control. Histological examination of the brain revealed vacuolation and neuronal necrosis at 1000 mg/kg body weight of the hydromethanolic stem extract of *Costus afer*. Vacuolation in brain parenchyma is a common histopathologic finding that can result from several potential mechanisms associated with excitotoxicity, prion disease and spongiform encephalopathies. Formation of vacuoles in or adjacent to brain cells are inconsequential when they are not observed with other pathologic findings. Neuronal necrosis in the brain is commonly the result of ischemia or any influence that impairs neuronal energy metabolism. In this study, the neuronal necrosis in the brain at 1000 mg/kg dose of the extract could not be linked to any pathologic findings and as such the extract can be said to have no deleterious effect on the brain of rats at the tested doses of the extract. The heart, uterus, spleen, ovaries and stomach of rats administered with 250, 500 and 1000 mg/kg body weight doses of the extract for 28 days presented no significant differences in histologic features when compared with the control (distilled water). The marked increase in corpus luteum observed at 250 mg/kg dose of the extract is a sign of ovulation and not toxicity. The effect of this extract on the liver as observed in this research does not agree with the hepatoprotective report of Ukpabi *et al*. (2012) and Tonkiri *et al*. (2015). This could be due to the differences in the experimental designs that involved the induction of oxidative stress and liver pathology respectively in the previously reported cases. Slight tubular necrosis observed at all the doses of the extract does not support the reported non-toxic effect on kidneys of rats administered with the aqueous leaf extract of *Costus afer* (Ezejiofor *et al*., 2013). Necrosis of secondary spermatogenic cells with leydig

cell necrosis observed at doses of 500 mg/kg and 1000 mg/kg may be an indication of toxicity to the testes as leydig cells are the primary sources of androgens and they play an important role in spermatogenesis, controlling sexual development and maintaining secondary sexual characteristics and behaviour. The toxic effect of this extract on the testes may be due to the presence of alkaloids (Wink, 2016) or flavonoids which have been reported to be capable of affecting male reproductive health (Galati and O'Brien, 2004).

Conclusion

Hydromethanolic stem extract of *Costus afer* may be toxic to the testes, kidneys and liver on sub-chronic administration and it is important to use this plant with caution in the traditional treatment of chronic disease conditions.

Acknowledgement

The technical assistance of Mr Bamidele Adetiba of the Histology Unit, Department of Anatomy, Ahmadu Bello University, Zaria. Nigeria and Mr Bitrus Achi of the Department of Pharmacology and Toxicology, Kaduna State University, Kaduna-Nigeria is highly appreciated.

References

Anaga AO, Njoku CJ, Ekejiuba ES, Esiaka MN, Asuzu IU (2004). Investigations of the methanolic leaf extract of *Costus afer* Ker-Gawl for pharmacological activities *in vitro* and *in vivo*. *Phytomedicine*. 11 (2-3), 242-248.

Aweke GH (2007). *Costus afer* Ker Gawl. In: Schmelzer GH. and Gurib-Fakim A.(Eds). Plant Resources of Tropical Africa (PROTA). Wageningen, Netherlands. Available: http: //database.prota.org/search.html (Accessed 23rd June, 2020).

Awouters F, Niemegeers CJ, Lemaerts FM, Janssen PA (1978). Delay of Castor oil diarrhoea in rats*:* A new way to evaluate inhibitors of prostaglandin biosynthesis*. J Pharmacol*. 30, 41- 45.

Bancroft JD and Clayton C. (2018). The Hematoxylins and Eosin. In: Survana SK, Layton C and Bancroft JD. editors. Bancroft's Theory and Practice of Histological Techniques. 8th Edition, Elsevier, China. P. 126-138.

Bidhe, RM, Ghosh, S. (2004). Acute and sub-chronic (28 day) oral toxicity study in rats fed with novel surfactants. AAPS Pharm Sci. 6(2):14

Edeoga HO. and Okoli BE (2000). Chromosome numbers of *Costus lucanusianus* (*Costaceae*) in Nigeria. *Folia Geobot.* 35, 315-318.

Ezejiofor AN, Orish CN and Orisakwe OE (2013). Effect of aqueous leaves extract of *Costus afer* Ker Gawl *(Zingiberaceae)* on the liver and kidney of male albino *Wistar rats*. *Anc. Sci. Life*. 33 (1), 4-9. doi: 10.4103/0257-7941.134554. PMCID: 4140021.

Galati G and O'Brien PJ (2004). Potential toxicity of flavonoids and other dietary phenolics: significance for their chemopreventive and anticancer properties. *Free Radic Biol Med.* 37(3), 287-303.

Guzman AI and Guerrero, RO (2002). Effecto hypoglycemiante de *Costus specious* (*Zingiberaceae*), en rats. *Vitea-Columbia.* 9, 51-57.

Iwu MM, Anyawu BN (1982). Phytotherapeutic profile of Nigerian herbs 1:

Anti-inflammatory and anti-arthritic agents. *J Ethnopharmacol.* 6, 263-74.

Lin RC, Hanquet B, Lacaille-Dubois MA (1996). *Aferoside* A. A steroidal saponin from *Costus afer*. *Phytochemistry.* 43, 665-8.

OECD (1995). Repeated dose 28 days oral toxicity study in rodents. *OECD guideline for the testing of chemicals* 407, 1-8.

OECD (2008). Acute Oral Toxicity – Up and Down Procedure: *OECD Guidelines for testing of chemicals*, 425: 1-27.

Okoko TC (2009). *Stem extracts from the monocot Costus afer ameliorates paracetamol induced tissue injury in rats*. *Int. J. Pure App. Sci.* 3, 21-25.

Ukpabi, CF, Agbafor, KN, Ndukwe, OK, Agwu, A and Nwachukwu, SN (2012). Phytochemical composition of *Costus afer* extract and its alleviation of carbon tetrachloride-induced oxidative stress and toxicity. *Int. J. Modern Bot.* 2 (5), 120-126.

Sofowora, A. (1993). Medicinal Plant and Traditional Medicine in Africa. Spectrum Books Limited, Ibadan. Nigeria. pp 1-2, 150-153.

Soladoye, MO and Oyesika OO (2008). Textbook of Medicinal Plants from Nigeria. University of Lagos Press, Lagos. Nigeria. p.628.

Taiwo AO and Bolanle AA (2003). The leaf essential oil of *Costus afer* Ker Gawl from Nigeria. *Flavour Frag. J.* 18, 309-11.

Tepongning RN, Mbah JN, Avoulou FL, Jerme MM, Ndanga E-K K. and Fekam, FB (2018). Hydroethanolic extracts of *Erigeron floribundus* and *Azadirachta indica* reduced *Plasmodium berghei parasitaemia in Balb/c* mice. *Evid-based Compl Al.* 2018: 5156710. doi: 10.1155/2018/5156710.

Tonkiri A, Essien EB Akaninwor JO and Ogbomade RS (2015). Protective effect of *Costus afer* on lipid profile and hepatic damage in ethanol-induced liver cirrhosis in rats. *Int. J. Biochem. Res. & Rev.* 6 (2), 53-61.

Trease, GE and Evans, WC. (2004) *Pharmacognosy* 13th Edition, Balliere, Tindall and Cansell Ltd. London

Udem, SU and Ezeasor, C. (2010). The acute and sub-chronic toxicity studies of aqueous leaf and stem bark extracts of *Costus afer* Ker Gawl. (Zingiberaceae) in mice. Compl Clin Pathol., 19:75-80. Doi 10.1007/s 00580-009-0906-8.

W.H.O (2013b). WHO Traditional Medicine Strategy 2014-2023. Geneva. Switzerland.

Wink M (2016). Alkaloids: Toxicology and Health Effects. Doi: 10.1016/B978-0-12-384947-2.00020-9